



PATIENT

Gracie Boucher

PRESENTING CLINICAL SIGNS

bloody diarrhea and not eating (on and off) for the last couple of months. vomited once.

SPECIES

Canine

RADIOGRAPHIC STUDY OF THE ABDOMEN

Right/left lateral and ventrodorsal views totaling 4 images available for review.

BREED

Poodle Miniature Mix

RADIOGRAPHIC FINDINGS

The patient is in thin body condition.

The abdominal serosal detail appears to be maintained.

SEX

Female Spayed

Extensive gastrointestinal aerophagia is noted. Other than that, the gastrointestinal tract appears to be mostly empty.

Part of the small intestine appears to be thick walled and turgid; however, radiographic assessment of which is inaccurate.

AGE

8 Years

The radiographic presentation of the kidneys, liver, splenic tail, and urinary bladder is considered within normal limits.

Early osseous remodeling of the lumbosacral end plates is seen.

INTERPRETED BY

Nele Eley, DVM
Dr. med. Vet. DipECVDI

RADIOGRAPHIC DIAGNOSIS

- Gastrointestinal maldigestion pattern with extensive aerophagia.

INTERPRETATION OF THE FINDINGS & FURTHER RECOMMENDATIONS

The radiographic study reveals a gastrointestinal maldigestion pattern with extensive aerophagia. Functional ileus appears likely based on the radiographic findings. There is no evidence of obstructive pathology. Owing to the chronic history of the patient's clinical signs, further definition by means of abdominal ultrasound is strongly recommended in this patient.

HOSPITAL NAME

Truscott Animal
Hospital

REFERRING VET

Dr. Medhat Meawad

INVOICE

51456

DATE

4-11-22



PATIENT

Gracie Boucher

SPECIES

Canine

BREED

Poodle Miniature Mix

SEX

Female Spayed

AGE

8 Years

INTERPRETED BY

Nele Eley, DVM
Dr. med. Vet. DipECVDI

HOSPITAL NAME

Truscott Animal
Hospital

REFERRING VET

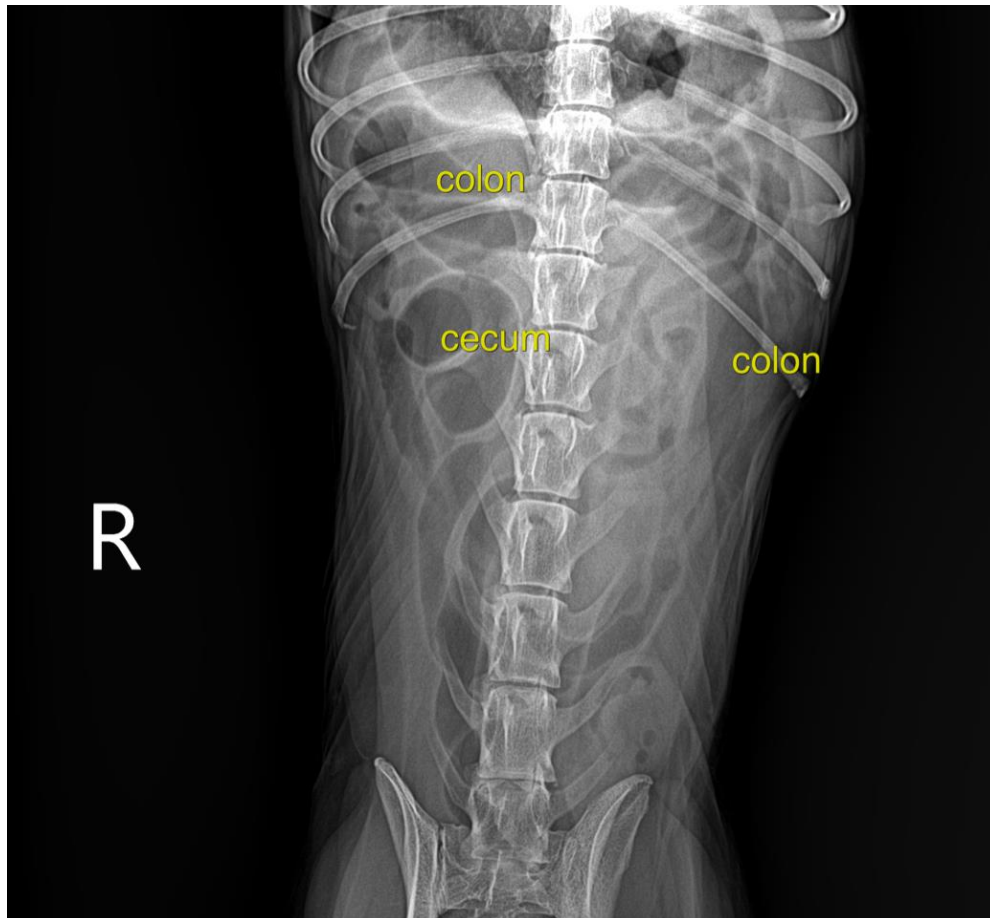
Dr. Medhat Meawad

INVOICE

51456

DATE

4-11-22



The information and recommendations provided are based on the images presented by the referring veterinarian/sonographer. No evaluation can be communicated regarding pathology that was not visible in the image/video clips provided.

Thank you for this referral. If the clinical or image interpretation does not parallel your findings or if I can be of any further assistance please contact me.

Nele Eley, DVM, Dr. med. vet., DipECVDI
European Specialist in Veterinary Diagnostic Imaging, Cert. Radiology,
Senior lecturer University of Giessen, Germany, Veterinary Faculty, Department of Radiology
Nele.Eley@sonopath.com