



PATIENT

Elvis Gicante

PRESENTING CLINICAL SIGNS

Vomiting for 2 days
Abnormal PE/Chem/CBC/UA Results: Blood work pending

SPECIES

Feline

RADIOGRAPHIC STUDY OF THE ABDOMEN

Right/left lateral and ventrodorsal views totaling 4 images available for review.

BREED

Domestic Shorthair

RADIOGRAPHIC FINDINGS

The abdominal serosal detail is maintained.

SEX

Male

The stomach contains a moderate amount of fluid and gas.

The descending duodenum is highlighted by gas as well and mildly rigid in appearance. The small intestinal loops are distributed throughout the mid abdomen and present no evidence of abnormal dilation, plication, or radiopaque foreign material.

AGE

17 Months

A moderate amount of fecal matter is seen within the colon.

RADIOGRAPHIC DIAGNOSIS

- Gastroduodenal maldigestion pattern.
- No radiographic signs of mechanical small intestinal ileus.
- Bilateral hypercalcemic nephropathy.

INTERPRETED BY

Nele Eley, DVM
Dr. med. Vet. DipECVDI

INTERPRETATION OF THE FINDINGS & FURTHER RECOMMENDATIONS

HOSPITAL NAME

Truscott Animal
Hospital

The radiographic study reveals no overt signs of mechanical intestinal ileus. Impaired gastric outflow, gastroenteritis, systemic illness, and metabolic changes all are potential underlying causes of the pertinent radiographic changes. Full internal medicine workup and abdominal ultrasound could be considered for further definition in case of persisting clinical signs.

REFERRING VET

Dr. Mena Abdelsayed

INVOICE

51454

DATE

4-11-22



PATIENT

Elvis Gicante

SPECIES

Feline

BREED

Domestic Shorthair

SEX

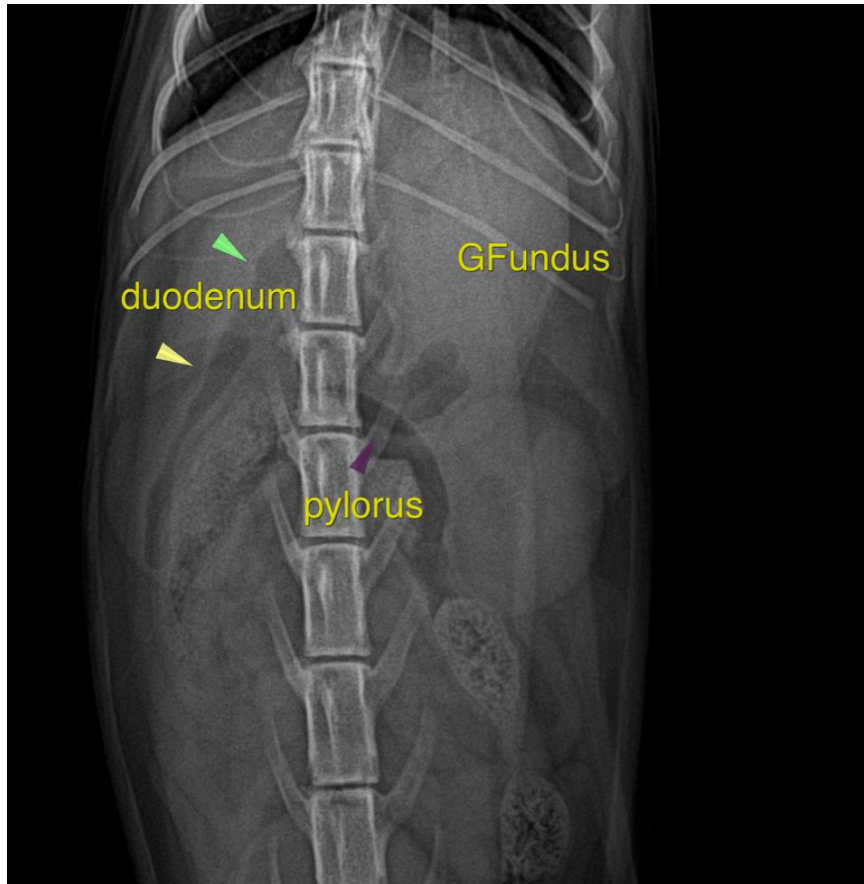
Male

AGE

17 Months

INTERPRETED BY

Nele Eley, DVM
Dr. med. Vet. DipECVDI



HOSPITAL NAME

Truscott Animal
Hospital

REFERRING VET

Dr. Mena Abdelsayed

INVOICE

51454

DATE

4-11-22

The information and recommendations provided are based on the images presented by the referring veterinarian/sonographer. No evaluation can be communicated regarding pathology that was not visible in the image/video clips provided.

Thank you for this referral. If the clinical or image interpretation does not parallel your findings or if I can be of any further assistance please contact me.

Nele Eley, DVM, Dr. med. vet., DipECVDI
European Specialist in Veterinary Diagnostic Imaging, Cert. Radiology,
Senior lecturer University of Giessen, Germany, Veterinary Faculty, Department of Radiology
Nele.Eley@sonopath.com