

**PATIENT**

Coco Karing

PRESENTING CLINICAL SIGNS

Pet presented today for a routine dental cleaning and extraction of retained deciduous teeth.

COMPUTED TOMOGRAPHIC STUDY OF THE DENTAL ARCADES**SPECIES**

Canine

Plain study available for review.

COMPUTED TOMOGRAPHIC FINDINGS**BREED**

Shih Tzu

The patient has a brachycephalic dentition with overlapping tooth roots in shortened maxillary and mandibular arcades.

Widening of the periodontal space of the triadans 104 and 204 is seen. A remnant of the deciduous 204 is present.

SEX

M

An irregular shaped enamel cap appears to be present on the occlusal surface of the triadans 108 and 109 which are not supposed to have deciduous teeth.

A remaining deciduous 404 is seen. The periodontal space of the triadans 304 and 404 presents mild generalized widening.

AGE

1 Year

COMPUTED TOMOGRAPHIC DIAGNOSIS

- Persisting remnants of the triadans 204 and 404.
- Suspect supernumerous and persisting deciduous teeth in the right maxillary molar region.
- Mild generalized widening of the periodontium of all canine teeth.

INTERPRETED BY

Nele Eley, DVM
Dr. med. Vet. DipECVDI

INTERPRETATION OF THE FINDINGS & FURTHER RECOMMENDATIONS**HOSPITAL NAME**

Cranberry Holistic
Pet Care

The periodontium of all canine teeth presents mild widening which may still be a function of the resorption and shedding of the deciduous teeth. Persisting remnants of the deciduous teeth of the triadans 204 and 404 are seen and were removed after the CT study. Presence of a supernumerous enamel cap or remnant in the right upper maxillary arcade should be double checked (see image below).

REFERRING VET

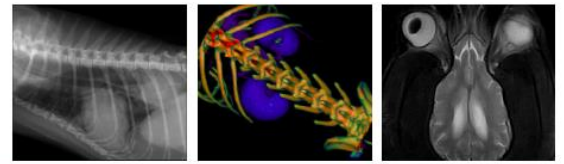
Cynthia Maro

INVOICE

51444

DATE

4-11-22



PATIENT

Coco Karing

SPECIES

Canine

BREED

Shih Tzu

SEX

M

AGE

1 Year

INTERPRETED BY

Nele Eley, DVM
Dr. med. Vet. DipECVDI

HOSPITAL NAME

Cranberry Holistic
Pet Care

REFERRING VET

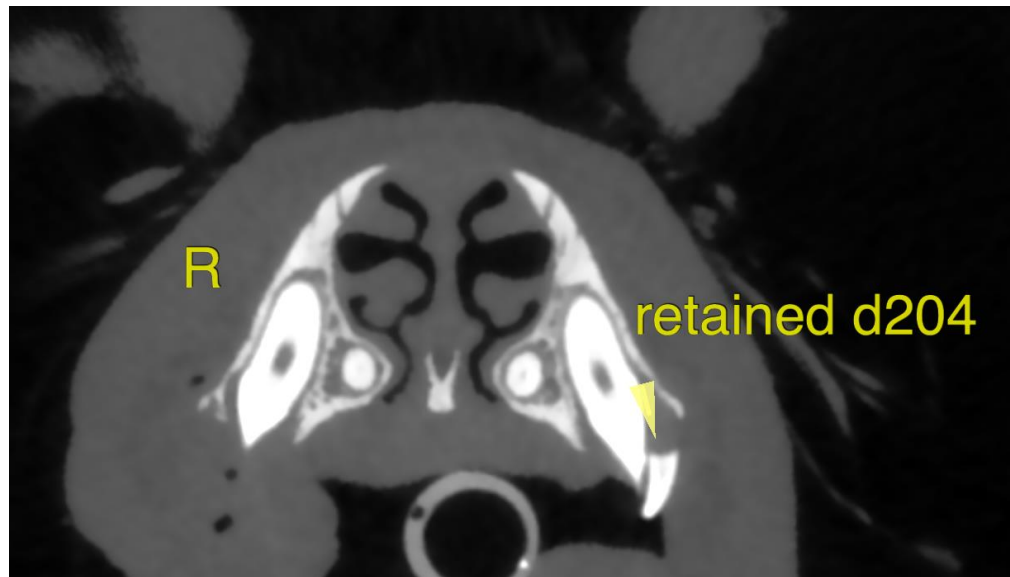
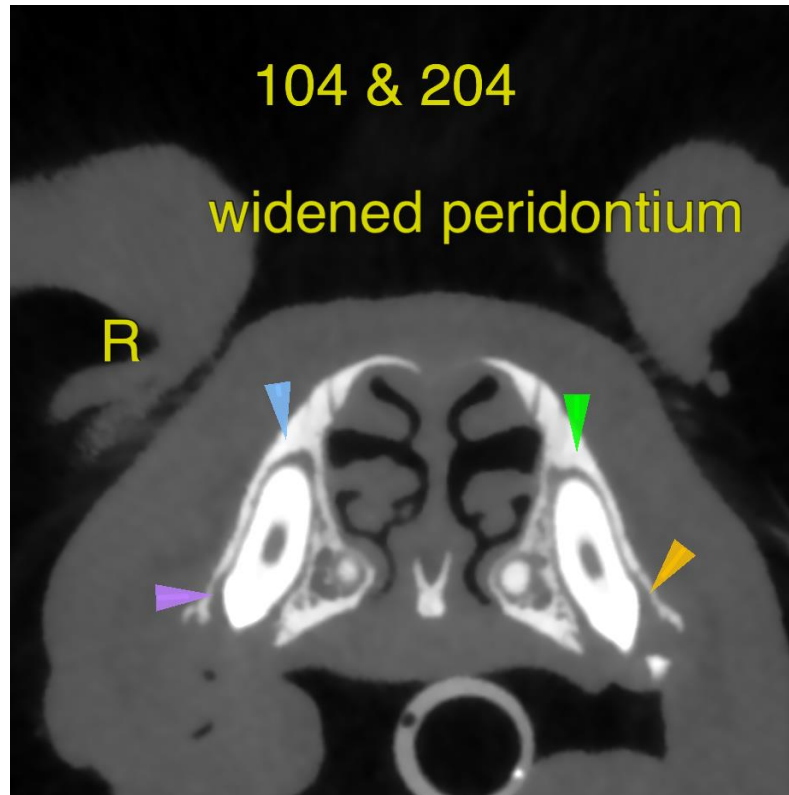
Cynthia Maro

INVOICE

51444

DATE

4-11-22





PATIENT

Coco Karing

SPECIES

Canine

BREED

Shih Tzu

SEX

M

AGE

1 Year

INTERPRETED BY

Nele Eley, DVM
Dr. med. Vet. DipECVDI

HOSPITAL NAME

Cranberry Holistic
Pet Care

REFERRING VET

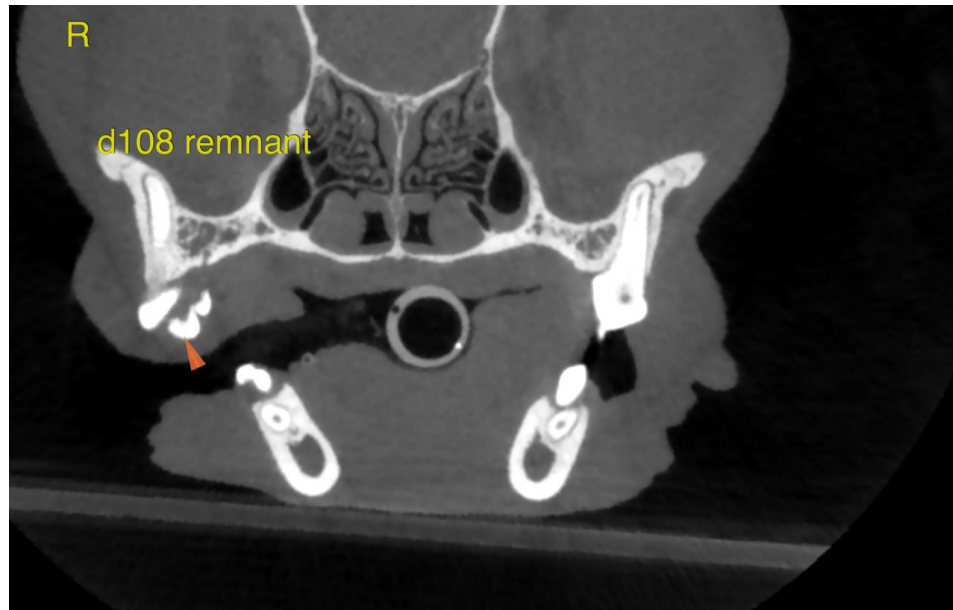
Cynthia Maro

INVOICE

51444

DATE

4-11-22



The information and recommendations provided are based on the images presented by the referring veterinarian/sonographer. No evaluation can be communicated regarding pathology that was not visible in the image/video clips provided.

Thank you for this referral. If the clinical or image interpretation does not parallel your findings or if I can be of any further assistance please contact me.

Nele Eley, DVM, Dr. med. vet., DipECVDI
European Specialist in Veterinary Diagnostic Imaging, Cert. Radiology,
Senior lecturer University of Giessen, Germany, Veterinary Faculty, Department of Radiology
Nele.Eley@sonopath.com