



**PATIENT**

Bill Muzones

**PRESENTING CLINICAL SIGNS**

vomiting since the weekend  
Abnormal PE/Chem/CBC/UA Results: High BUN

**SPECIES**

Canine

**RADIOGRAPHIC STUDY OF THE ABDOMEN**

Right/left lateral and ventrodorsal views totaling 4 images available for review.

**BREED**

Terrier Mix

**RADIOGRAPHIC FINDINGS**

A subcutaneous lipoma is seen in the ventral thoracic wall.

Intervertebral disc space collapse, vertebral end plate sclerosis, and spondylosis deformans are seen at T12/13 and T13/L1.

**SEX**

Male Neutered

The L1/2 intervertebral disc is mineralized.

The abdominal serosal detail is maintained.

**AGE**

15 Years

The stomach appears to be empty.

The small intestinal loops present a segmental gas pattern and are turgid in appearance. No evidence of abnormal dilation, plication, or radiopaque foreign material is seen.

**INTERPRETED BY**

Nele Eley, DVM  
Dr. med. Vet. DipECVDI

The colon is mostly empty.

**RADIOGRAPHIC DIAGNOSIS**

- Intestinal maldigestion pattern with no signs of mechanical ileus.

**HOSPITAL NAME**

Truscott Animal  
Hospital

**INTERPRETATION OF THE FINDINGS & FURTHER RECOMMENDATIONS**

The radiographic study reveals no evidence of mechanical small intestinal ileus. Functional ileus is considered likely based on the radiographic findings and further definition by means of abdominal ultrasound should be considered if not performed already to further define the potential cause of the vomiting in this patient.

**REFERRING VET**

Dr. Mena Abdelsayed

**INVOICE**

51453

**DATE**

4-11-22



**PATIENT**

Bill Muzones

**SPECIES**

Canine

**BREED**

Terrier Mix

**SEX**

Male Neutered

**AGE**

15 Years

**INTERPRETED BY**

Nele Eley, DVM  
Dr. med. Vet. DipECVDI

**HOSPITAL NAME**

Truscott Animal  
Hospital

**REFERRING VET**

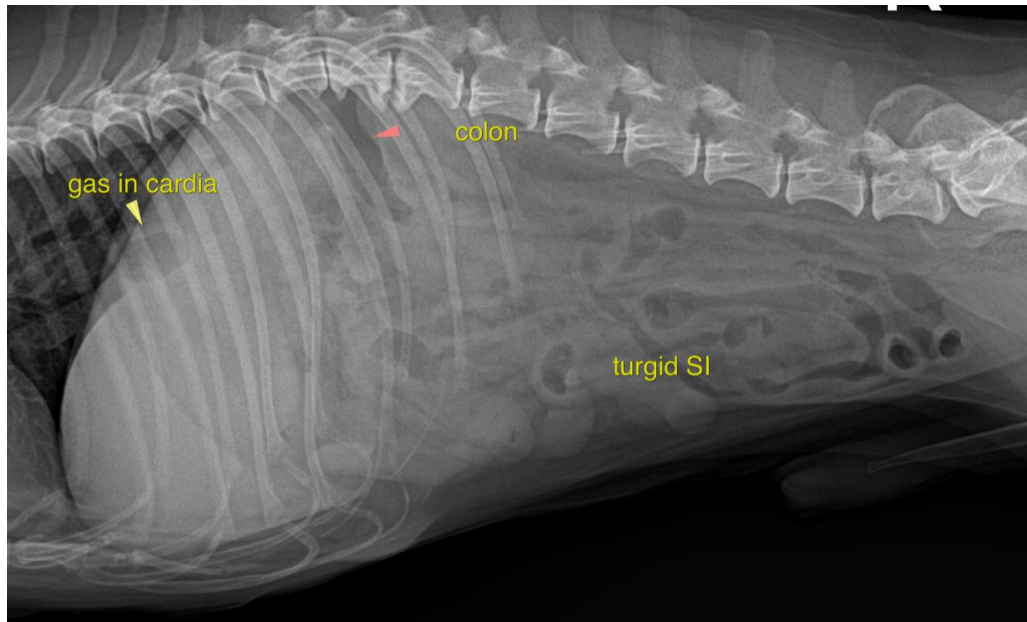
Dr. Mena Abdelsayed

**INVOICE**

51453

**DATE**

4-11-22



The information and recommendations provided are based on the images presented by the referring veterinarian/sonographer. No evaluation can be communicated regarding pathology that was not visible in the image/video clips provided.

Thank you for this referral. If the clinical or image interpretation does not parallel your findings or if I can be of any further assistance please contact me.

**Nele Eley, DVM, Dr. med. vet., DipECVDI**  
European Specialist in Veterinary Diagnostic Imaging, Cert. Radiology,  
Senior lecturer University of Giessen, Germany, Veterinary Faculty, Department of Radiology  
Nele.Eley@sonopath.com