

**PATIENT PRESENTING CLINICAL SIGNS**

Princess Menendez Presented for evaluation of mass within right external ear canal. Biopsy results pending.  
Abnormal PE/Chem/CBC/UA Results: FeLV/FIV - neg

**SPECIES COMPUTED TOMOGRAPHIC STUDY OF THE HEAD**

Feline Plain and post contrast studies available for review.

**COMPUTED TOMOGRAPHIC FINDINGS****BREED**

DSH

The right tympanic bulla is filled with fluid attenuating material. Swelling of the peripheral mucosal lining of the tympanic bulla is seen. There is moderate thickening of the osseous wall of the tympanic bulla. No evidence of intracranial extension is seen at this point.

**SEX**

Female

There is an elongated, approximately 20mm long and 7mm wide mass expanding the right external auditory meatus which extends from the entrance into the tympanic bulla into the opening of the vertical canal. Peripheral rim enhancement is noted. The mass is well defined, and no evidence of peripheral tissue infiltration is seen.

**AGE**

9 Months

The right medial retropharyngeal lymph node is mildly enlarged and presents mildly increased contrast enhancement.

The left tympanic bulla and left external auditory meatus present within normal limits.

**INTERPRETED BY**

Nele Eley (Ondreka),  
DVM Dr. med. vet.,  
DipECVDI

**COMPUTED TOMOGRAPHIC DIAGNOSIS**

- Chronic right hand sided otitis media with large chronic inflammatory ear canal polyp.
- Right medial retropharyngeal lymphadenitis.

**INTERPRETATION OF FINDINGS & FURTHER RECOMMENDATIONS****HOSPITAL NAME**

Mobile Pet Imaging

The CT findings are compatible with a chronic inflammatory polyp expanding the right external auditory meatus. Signs of right hand sided chronic otitis media are seen. Infectious middle ear disease is considered likely. There is no evidence of intracranial extension of the otitis media at this point.

The changes of the retropharyngeal lymph node are compatible with reactive lymphadenitis.

**REFERRING VET**

Seraydar

**INVOICE**

57717

**DATE**

4-10-23



**PATIENT**

Princess Menendez

**SPECIES**

Feline

**BREED**

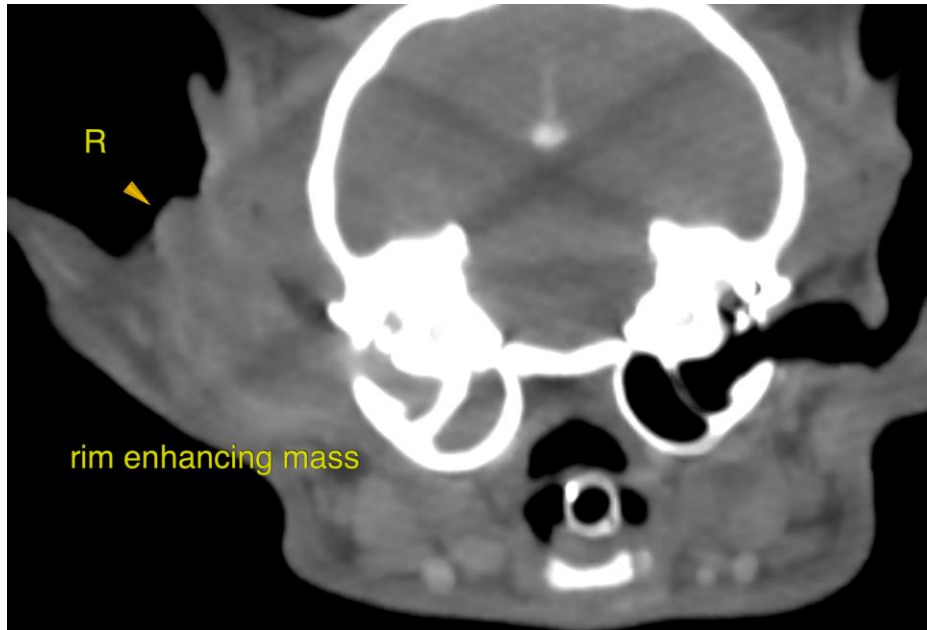
DSH

**SEX**

Female

**AGE**

9 Months



The information and recommendations provided are based on the images presented by the referring veterinarian. No evaluation can be communicated regarding pathology that was not visible in the image/video clips provided.

**INTERPRETED BY**

Nele Eley (Ondreka),  
DVM Dr. med. vet.,  
DipECVDI

Thank you for this referral. If the clinical or image interpretation does not parallel your findings or if I can be of any further assistance please contact me.

**Nele Eley (Ondreka)**, DVM, Dr. med. vet., DipECVDI  
European Specialist in Veterinary Diagnostic Imaging, Cert. Radiology,  
Senior lecturer University of Giessen/Germany, Veterinary Faculty, Department of Radiology.  
Nele.Eley@sonopath.com

**HOSPITAL NAME**

Mobile Pet Imaging

**REFERRING VET**

Seraydar

**INVOICE**

57717

**DATE**

4-10-23