



PATIENT

Ellie Christa Webb

PRESENTING CLINICAL SIGNS

Coughing for several months, slow unplanned weight loss, previous empiric treatment with doxycycline didn't cause improvement even during treatment.
Abnormal PE/Chem/CBC/UA Results: CBC, chem, T4 were normal in December 2021

SPECIES

Feline

RADIOGRAPHIC STUDY OF THE THORAX

Right/left lateral and ventrodorsal views totaling 3 images available for review.

BREED

DSH

RADIOGRAPHIC FINDINGS

The lungs are deeply inflated. A moderate generalized bronchial lung pattern with peribronchial cuffing is seen. A single nodular opacity is associated with the left cranial lung lobe and can be seen level with the third intercostal space on the orthogonal view (see image below).

SEX

Female Spayed

There is no radiographic evidence of cardiovascular pathology.

Course and width of the trachea are considered within normal limits.

AGE

9.5 Years

No evidence of mediastinal widening is noted.

RADIOGRAPHIC DIAGNOSIS

- Moderate bronchial lung pattern with peribronchial cuffing.
- Nodular opacity left cranial lung lobe.

INTERPRETED BY

Nele Eley, DVM
Dr. med. Vet. DipECVDI

INTERPRETATION OF THE FINDINGS & FURTHER RECOMMENDATIONS

The radiographic findings are suggestive for active chronic lower airway disease. Owing to the history of lacking treatment response to antimicrobial treatment, allergic lower airway syndrome appears more likely than infectious bronchitis. However, viral, bacterial, parasitic, and protozoal infection cannot be ruled out entirely.

HOSPITAL NAME

Friendship Springs
Veterinary Care

The nodular opacity of the left cranial lung lobe may represent peribronchial inflammatory infiltrate, fibrotic nodule, mucus plugging, and less likely pulmonary neoplasia or granuloma.

REFERRING VET

Trae Cutchin

Airway sampling could be considered for further definition. Recheck radiographs or CT could be considered to further define the character of the nodule in the left cranial lung lobe.

INVOICE

51439

DATE

4-10-22



PATIENT

Ellie Christa Webb

SPECIES

Feline

BREED

DSH

SEX

Female Spayed

AGE

9.5 Years

INTERPRETED BY

Nele Eley, DVM
Dr. med. Vet. DipECVDI

HOSPITAL NAME

Friendship Springs
Veterinary Care

REFERRING VET

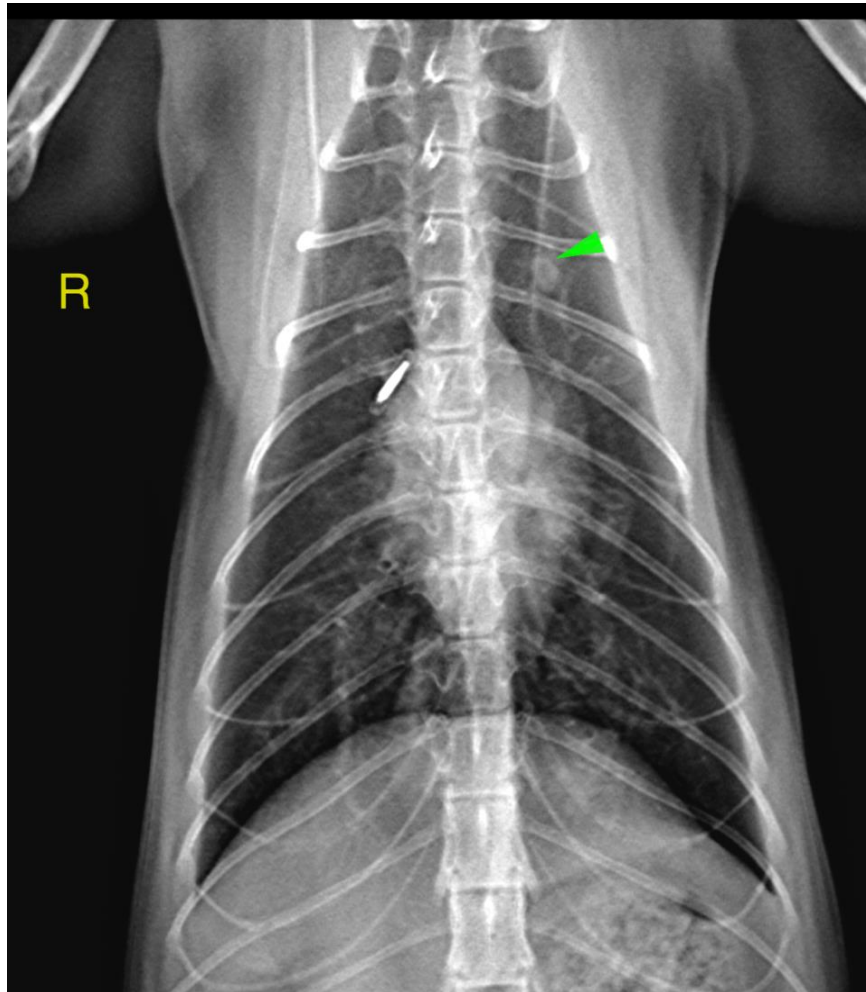
Trae Cutchin

INVOICE

51439

DATE

4-10-22



The information and recommendations provided are based on the images presented by the referring veterinarian/sonographer. No evaluation can be communicated regarding pathology that was not visible in the image/video clips provided.

Thank you for this referral. If the clinical or image interpretation does not parallel your findings or if I can be of any further assistance please contact me.

Nele Eley, DVM, Dr. med. vet., DipECVDI
European Specialist in Veterinary Diagnostic Imaging, Cert. Radiology,
Senior lecturer University of Giessen, Germany, Veterinary Faculty, Department of Radiology
Nele.Eley@sonopath.com