



**PATIENT PRESENTING CLINICAL SIGNS**

Cloud Haskett P presented for acute onset of limbing/lameness of the hindlimbs. O's noted that they thought the P may have injured themselves (running into pole) when chasing pigeons in the backyard. P has a history of compression activity (such as jumping on and off of furniture). P has previously been diagnosed with MPL (Grade I-II), which could not be evaluated due to abnormalities seen on exam today.

**SPECIES**

Canine Abnormal PE/Chem/CBC/UA Results: Severe ataxia of the hindlimbs (worse on right hindlimb) - forelimbs ROM WNL. CP deficits of the hindlimbs, with P unable to stand unaided for moderate amount of time - P returns to seated position when possible No apparent pain on evaluation of the hips/back/cervical neck

**BREED**

Maltipoo **RADIOGRAPHIC STUDY OF THE THORACOLUMBAR SPINE**

Lateral and ventrodorsal views totaling 3 images available for review.

**SEX**

**RADIOGRAPHIC FINDINGS**

Male Neutered Moderate intervertebral disc space narrowing of the intervertebral disc T12/13 is noted consistently on all available images.

**AGE**

Intervertebral disc mineralization is present at T11/12.

6 Years

The remainder of the thoracolumbar vertebrae present within normal limits in terms of their general anatomy and alignment.

**INTERPRETED BY**

Nele Eley, DVM  
Dr. med. Vet. DipECVDI

**RADIOGRAPHIC DIAGNOSIS**

- Moderate intervertebral disc space collapse suggesting disc disease within the caudal thoracic spine T12/13.

**HOSPITAL NAME**

**INTERPRETATION OF THE FINDINGS & FURTHER RECOMMENDATIONS**

Boca Park Animal Hospital

The narrowing of the intervertebral disc space T12/13 is significant and consistent and may represent a site of disc herniation. Differential diagnosis includes disc extrusion, disc protrusion, and uncomplicated degenerative disc disease. Further definition and evaluation for the concurrent presence of potential compressive myelopathy requires a myelogram or cross sectional imaging.

**REFERRING VET**

Tifanie Silver

**INVOICE**

51440

**DATE**

4-10-22



**PATIENT**

Cloud Haskett

**SPECIES**

Canine

**BREED**

Maltipoo

**SEX**

Male Neutered

**AGE**

6 Years

**INTERPRETED BY**

Nele Eley, DVM  
Dr. med. Vet. DipECVDI

**HOSPITAL NAME**

Boca Park Animal  
Hospital

**REFERRING VET**

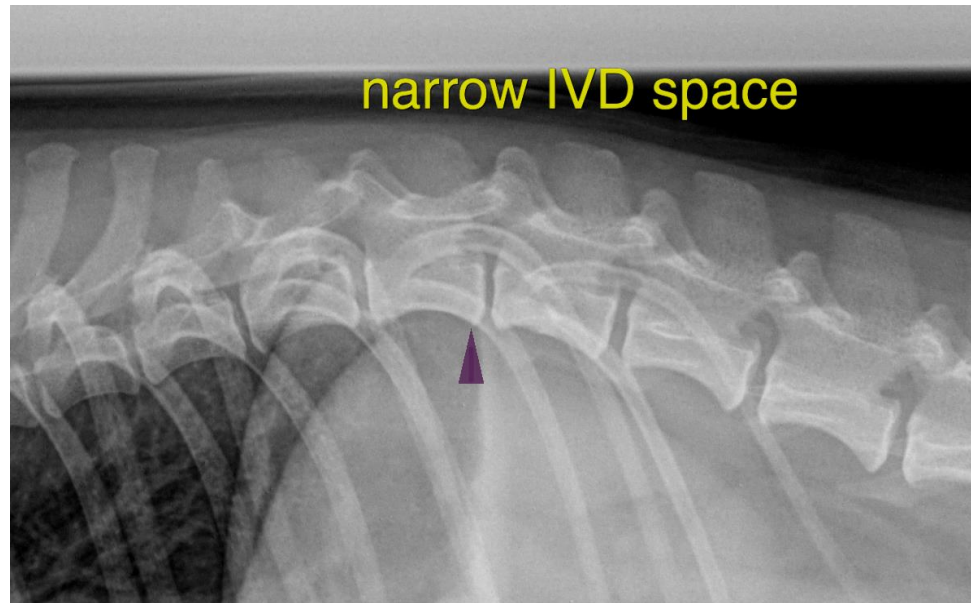
Tifanie Silver

**INVOICE**

51440

**DATE**

4-10-22



The information and recommendations provided are based on the images presented by the referring veterinarian/sonographer. No evaluation can be communicated regarding pathology that was not visible in the image/video clips provided.

Thank you for this referral. If the clinical or image interpretation does not parallel your findings or if I can be of any further assistance please contact me.

**Nele Eley**, DVM, Dr. med. vet., DipECVDI  
European Specialist in Veterinary Diagnostic Imaging, Cert. Radiology,  
Senior lecturer University of Giessen, Germany, Veterinary Faculty, Department of Radiology  
Nele.Eley@sonopath.com