



PATIENT PRESENTING CLINICAL SIGNS

- Kelsie Miller
- Hx of CKD - dx a few weeks ago
 - POCUS at VEG showed left kidney was severely dilated and the right was also enlarged. Concerned for bilateral hydronephrosis.

SPECIES

Canine

COMPUTED TOMOGRAPHIC STUDY OF THE ABDOMEN

Plain and post contrast studies are available for review.

BREED

Chihuahua

COMPUTED TOMOGRAPHIC FINDINGS

Both kidneys are severely enlarged, the parenchyma is distorted and displaced by multicystic masses in both kidneys. Faint mineralizations appear to be present in the left kidney. The organ architecture is severely disrupted, normal corticomedullary differentiation is not discernible. The renal pelvis, ureters and urinary bladder are not adequately visualized, and the extent of involvement is unclear. There is a severe mass effect due to the bilateral renomegaly with organ displacement.

SEX

FS

The adrenal glands, liver, stomach and spleen appear within normal limits except for their displacement.

AGE

12yr

COMPUTED TOMOGRAPHIC DIAGNOSIS

- Bilateral severe multicystic large renal masses causing complete distortion of normal renal architecture

INTERPRETED BY

Nele Eley (Ondreka),
DVM Dr. med. vet.,
DipECVDI

INTERPRETATION OF FINDINGS & FURTHER RECOMMENDATIONS

Differential considerations include bilateral polycystic kidney disease, cystic renal neoplasia and less likely severe chronic kidney disease with cystic transformation. The masses, ureters and urinary bladder could not be fully evaluated due to field of view limitations. Obstruction or other secondary changes cannot be excluded.

HOSPITAL NAME

Paws & Claws Urgent
Care

Etiology remains uncertain without further imaging and/ or histopathology. Repeat CT or abdominal ultrasound with larger field of view can be considered.

REFERRING VET

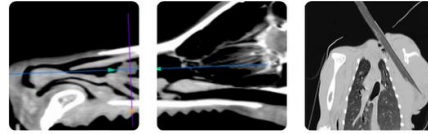
Shakira Jameson

INVOICE

24373

DATE

04/01/2026



PATIENT

Kelsie Miller

SPECIES

Canine

BREED

Chihuahua

SEX

FS

AGE

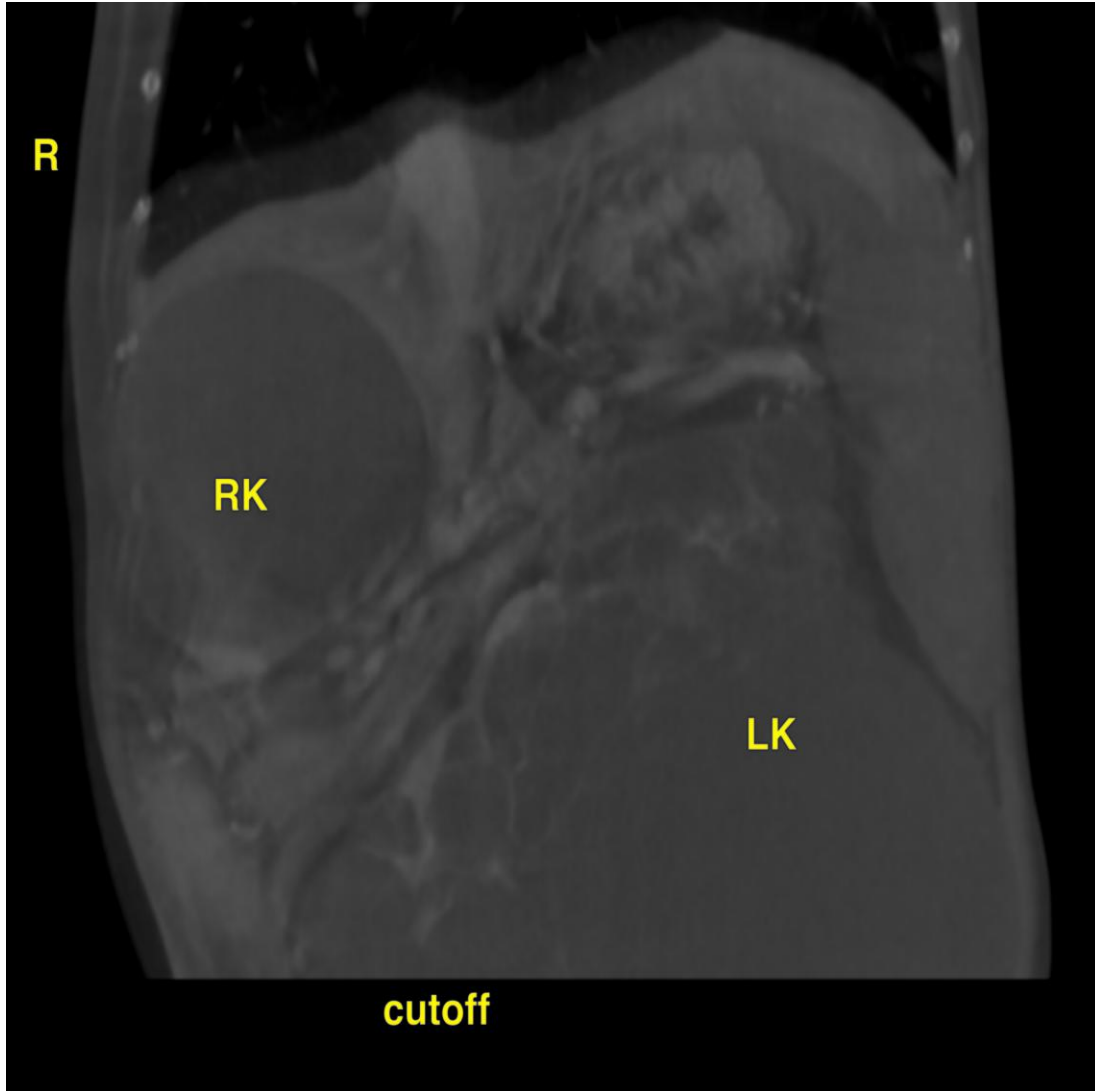
12yr

INTERPRETED BY

Nele Eley (Ondreka),
DVM Dr. med. vet.,
DipECVDI

HOSPITAL NAME

Paws & Claws Urgent
Care



REFERRING VET

Shakira Jameson

The information and recommendations provided are based on the images presented by the referring veterinarian. No evaluation can be communicated regarding pathology that was not visible in the image/video clips provided.

Thank you for this referral. If the clinical or image interpretation does not parallel your findings or if I can be of any further assistance please contact me.

INVOICE

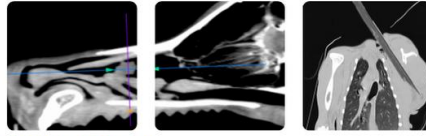
24373

Nele Eley (Ondreka), DVM, Dr. med. vet., DipECVDI
European Specialist in Veterinary Diagnostic Imaging, Cert. Radiology,
Senior lecturer University of Giessen/Germany, Veterinary Faculty, Department of Radiology.

DATE

info@sonopath.com

04/01/2026



Teleradiology

Educational Teleconsultation Services™

PATIENT

Kelsie Miller

SPECIES

Canine

BREED

Chihuahua

SEX

FS

AGE

12yr

INTERPRETED BY

Nele Eley (Ondreka),
DVM Dr. med. vet.,
DipECVDI

HOSPITAL NAME

Paws & Claws Urgent
Care

REFERRING VET

Shakira Jameson

INVOICE

24373

DATE

04/01/2026