

PATIENT PRESENTING CLINICAL SIGNS

Billy Billy Ear Polyp present-surgical planning needed

COMPUTED TOMOGRAPHIC STUDY OF THE HEAD

SPECIES

Feline

Plain and post contrast studies are available for review.

COMPUTED TOMOGRAPHIC FINDINGS

BREED

DSH

A 15 mm x 4 mm sized well delineated pedunculated mass with peripheral enhancement was seen in the right external ear canal. Thickening of the epithelial lining and fluid are seen within the remainder of the canal.

SEX

MN

The right tympanic bulla is filled with fluid attenuating material and presents thickening of its osseous lining. There is no evidence of intracranial extension.

The left tympanic bulla presents within normal limits. A small amount of fluid is seen in the medial aspect of the left ear canal.

AGE

3yr

The right retropharyngeal and right parotid lymph nodes are mildly enlarged.

COMPUTED TOMOGRAPHIC DIAGNOSIS

- Chronic inflammatory right ear canal polyp with chronic otitis media
- Mild right sided reactive lymphadenopathy
- Mild left sided otitis externa

INTERPRETED BY

Nele Eley (Ondreka),
DVM Dr. med. vet.,
DipECVDI

INTERPRETATION OF FINDINGS & FURTHER RECOMMENDATIONS

The findings are consistent with chronic right sided otitis media with a benign chronic inflammatory polyp extending into the right ear canal. Regional lymphadenopathy is seen consistent with reactive change. No CT evidence of intracranial extension of the otitis media is present.

HOSPITAL NAME

Green Prairie AH

Polyp removal and treatment of otitis externa and media is recommended. Perform C/S as well as histopathology of polyp and bulla fluid at surgery.

REFERRING VET

Coble Animal
Hospital

INVOICE

24370

DATE

04/01/2026



PATIENT

Billy Billy

SPECIES

Feline

BREED

DSH

SEX

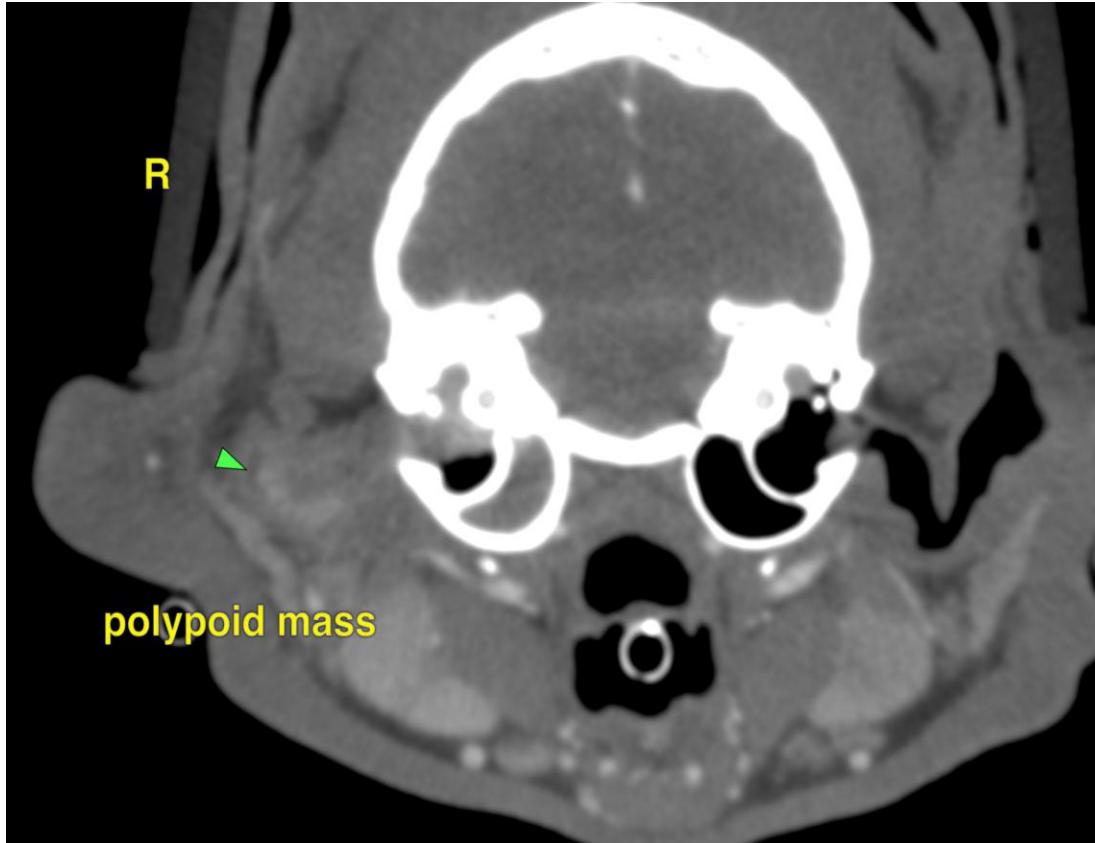
MN

AGE

3yr

INTERPRETED BY

Nele Eley (Ondreka),
DVM Dr. med. vet.,
DipECVDI



The information and recommendations provided are based on the images presented by the referring veterinarian. No evaluation can be communicated regarding pathology that was not visible in the image/video clips provided.

HOSPITAL NAME

Green Prairie AH

Thank you for this referral. If the clinical or image interpretation does not parallel your findings or if I can be of any further assistance please contact me.

REFERRING VET

Coble Animal
Hospital

Nele Eley (Ondreka), DVM, Dr. med. vet., DipECVDI
European Specialist in Veterinary Diagnostic Imaging, Cert. Radiology,
Senior lecturer University of Giessen/Germany, Veterinary Faculty, Department of Radiology.
info@sonopath.com

INVOICE

24370

DATE

04/01/2026



PATIENT

Billy Billy

SPECIES

Feline

BREED

DSH

SEX

MN

AGE

3yr

INTERPRETED BY

Nele Eley (Ondreka),
DVM Dr. med. vet.,
DipECVDI

HOSPITAL NAME

Green Prairie AH

REFERRING VET

Coble Animal
Hospital

INVOICE

24370

DATE

04/01/2026