
PATIENT PRESENTING CLINICAL SIGNS

Trixie Attreed facial swelling with hx of epistaxis

COMPUTED TOMOGRAPHIC STUDY OF THE HEAD
SPECIES

Plain and post-contrast studies available for review.

Feline

COMPUTED TOMOGRAPHIC FINDINGS
BREED

Tuxedo

A large, soft tissue attenuating, ill-defined soft tissue mass is seen within the mid third of the right nasal cavity. The mass measures approximately 2.0 cm in width and 1.5 cm in length. The center of the mass is fluid attenuating. Multiple cavitations with heterogeneous contrast enhancement is noted. There is extensive regional turbinate lysis as well as lysis of the right nasal maxillary bone and right bony orbita, allowing for extension into the rostral and nasal aspect of the right orbita. The mass also extends onto the dorsum of the nose and the right side of the face.

SEX

Spayed Female

The cribriform plate is intact.

Obstructive right frontal sinusitis is noted.

AGE

11 Years

The right submandibular and medial retropharyngeal lymph nodes are moderately enlarged.

COMPUTED TOMOGRAPHIC DIAGNOSIS

- Soft tissue mass with aggressive biological behavior in the right nasal cavity with extension into the face and right orbita.
- Right medial retropharyngeal and submandibular lymphadenomegaly.

INTERPRETED BY

Nele Eley (Ondreka),
 DVM Dr. med. vet.,
 DipECVDI

INTERPRETATION OF FINDINGS & FURTHER RECOMMENDATIONS
HOSPITAL NAME

Stone Cottage VH

The CT findings are compatible with a malignant neoplasia within the right nasal cavity with extension into the right side of the face and right orbita. Differential diagnoses include adenocarcinoma, other carcinoma, lymphosarcoma, fibrosarcoma, and other. Final diagnosis would require sampling for histology.

REFERRING VET

Dr. Spaccarelli

The lymph node changes are equivocal for reactive hyperplasia versus early metastatic disease. Consider fine needle aspiration for further definition.

INVOICE

36701

DATE

4/1/22



PATIENT

Trixie Attreed

SPECIES

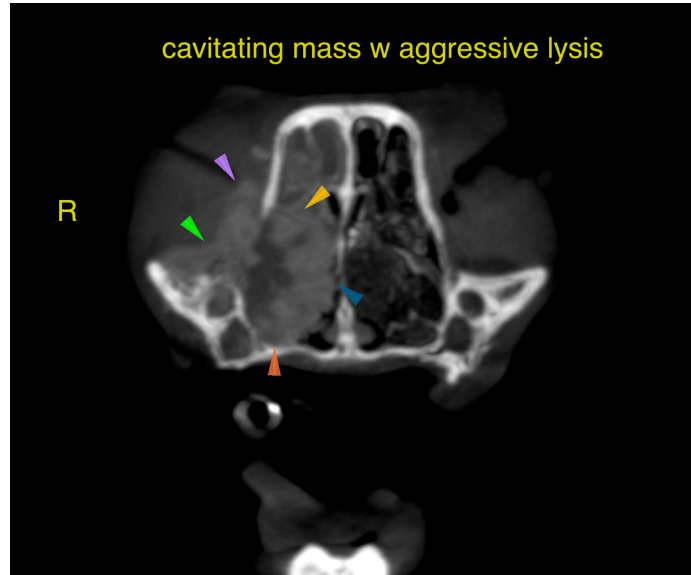
Feline

BREED

Tuxedo

SEX

Spayed Female



AGE

11 Years

The information and recommendations provided are based on the images presented by the referring veterinarian. No evaluation can be communicated regarding pathology that was not visible in the image/video clips provided.

Thank you for this referral. If the clinical or image interpretation does not parallel your findings or if I can be of any further assistance please contact me.

INTERPRETED BY

Nele Eley (Ondreka),
DVM Dr. med. vet.,
DipECVDI

Nele Eley (Ondreka), DVM, Dr. med. vet., DipECVDI
European Specialist in Veterinary Diagnostic Imaging, Cert. Radiology,
Senior lecturer University of Giessen/Germany, Veterinary Faculty, Department of Radiology.
Nele.Eley@sonopath.com

HOSPITAL NAME

Stone Cottage VH

REFERRING VET

Dr. Spaccarelli

INVOICE

36701

DATE

4/1/22