


PATIENT PRESENTING CLINICAL SIGNS

Coconut Primera P has been vomiting and having diarrhea since Tuesday P is also not eating well e/d/u/d ok no c/s/v/d o feeds some kibble, if still hungry gives some type of cooked turkey breast o gives the fortiflora, she won't always take the famotidine pills

SPECIES RADIOGRAPHIC STUDY OF THE THORAX & ABDOMEN

Canine Right/left lateral and ventrodorsal views of the thorax, right lateral and ventrodorsal views of the abdomen totaling 6 images available for review.

BREED RADIOGRAPHIC FINDINGS

Chihuahua Abdomen
 The patient is obese.

SEX Microhepatica is noted.

Spayed Female The stomach presents aerophagia. The small intestinal loops are turgid in appearance. No evidence of abnormal dilation, plication or radiopaque foreign material.

AGE The abdominal serosal detail appears to be maintained.

2 Years The kidneys, spleen and urinary bladder present within normal limits.

Thorax
 The cardiac silhouette is upright and thin.

INTERPRETED BY

Nele Eley (Ondreka),
 DVM Dr. med. vet.,
 DipECVDI
 The caudal vena cava is thin.
 Course and width of the trachea are considered within normal limits.
 Lung and bronchial tree are considered within normal limits.

HOSPITAL NAME

Animal Paradise
 Hospital
 There is no evidence of abnormal mediastinal widening.

RADIOGRAPHIC DIAGNOSIS
REFERRING VET

- Gastrointestinal maldigestion pattern without radiographic evidence of mechanical ileus
- Hypovolemia with microcardia and underperfusion of the lung

Dr. Kristen Hellwarth

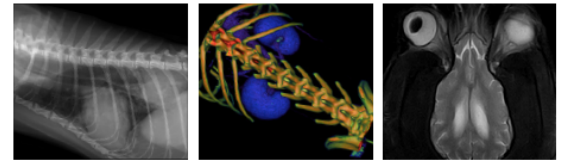
INTERPRETATION OF FINDINGS & FURTHER RECOMMENDATIONS

INVOICE The radiographic findings parallel the patient history. The gastrointestinal maldigestion pattern is seen. No evidence of abnormal dilation, plication, or radiopaque foreign material is noted. The radiographic findings support functional rather than mechanical ileus. Further definition by means of abdominal ultrasound could be considered in case of persisting or deteriorating clinical signs.

36707

DATE

4/1/22



PATIENT

Coconut Primera

SPECIES

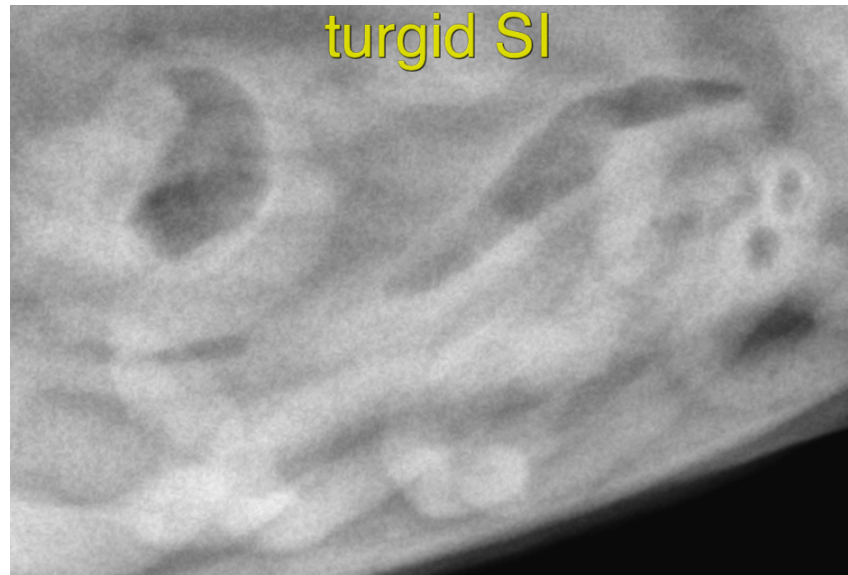
Canine

BREED

Chihuahua

SEX

Spayed Female



AGE

2 Years

The information and recommendations provided are based on the images presented by the referring veterinarian. No evaluation can be communicated regarding pathology that was not visible in the image/video clips provided.

Thank you for this referral. If the clinical or image interpretation does not parallel your findings or if I can be of any further assistance please contact me.

INTERPRETED BY

Nele Eley (Ondreka),
DVM Dr. med. vet.,
DipECVDI

Nele Eley (Ondreka), DVM, Dr. med. vet., DipECVDI
European Specialist in Veterinary Diagnostic Imaging, Cert. Radiology,
Senior lecturer University of Giessen/Germany, Veterinary Faculty, Department of Radiology.
Nele.Eley@sonopath.com

HOSPITAL NAME

Animal Paradise
Hospital

REFERRING VET

Dr. Kristen Hellwarth

INVOICE

36707

DATE

4/1/22