



PATIENT PRESENTING CLINICAL SIGNS

Snoopy Weisbach Growths in both external ear canals (R>>>L) and possibly also in his middle ear(s)

COMPUTED TOMOGRAPHIC STUDY OF THE HEAD & THORAX

SPECIES Plain and post contrast studies of the head and post contrast study of the thorax available for review.

Canine

COMPUTED TOMOGRAPHIC FINDINGS

BREED Thorax

Coonhound The bony and surrounding soft tissue structures are within normal limits.

SEX The sternal, cranial mediastinal and tracheobronchial lymph nodes are small elongated with a normal short-to-long-axis-ratio is < 0.5, the attenuation and contrast enhancement pattern are uniform and considered within normal limits.

Neutered Male The cardiovascular structures including the pulmonary vasculature are within normal limits.

AGE No evidence of interstitial pulmonary nodules or masses are seen. The bronchopulmonary structures present within normal limits. Occasional age related incidental pulmonary osteomas are seen.

7 Years Small incidental gas pockets are seen within the esophageal lumen, there is no evidence of abnormal dilation.

INTERPRETED BY Head

Nele Eley (Ondreka), DVM Dr. med. vet., DipECVDI The brain presents no deviation from normal anatomy and symmetry. The grey and white matter distinction and the neuroparenchymal attenuation are as expected. The distribution of contrast enhancement is within normal limits throughout the parenchyma and meninges. The ventricular system is non-dilated and within the limits of the expected volume and symmetry.

HOSPITAL NAME Thin and smoothly folded conchae and turbinates with even smooth mucosal lining. The osseous lining of the nasal cavities is intact.

Mobile Pet Imaging Both temporomandibular joints present congruent joint spaces with even subchondral bone surfaces and are considered within normal limits.

REFERRING VET Multiple soft tissue attenuating irregular shaped growths are emerging from the epithelial lining of the external auditory meatuses in their horizontal portions. The growths vary in size and measure up to 7mm in diameter. The changes are bilaterally symmetric, however, slightly more pronounced on the right hand side. The tympanic bullae and inner ear present within normal limits.

INVOICE The submandibular and medial retropharyngeal lymph nodes are small and elongated with a normal short-to-long-axis-ratio is < 0.5, the attenuation and contrast enhancement pattern is uniform.

57179

The salivary glands present within normal limits.

DATE The visible dentition is within normal limits.

3-9-23



PATIENT **COMPUTED TOMOGRAPHIC DIAGNOSIS**

Snoopy Weisbach

- Multiple polypoid growths within the medial aspects of the external auditory meatuses with no evidence of middle or inner ear involvement.
- No evidence of regional lymphadenomegaly.
- No evidence of pulmonary metastases.

SPECIES

Canine

INTERPRETATION OF FINDINGS & FURTHER RECOMMENDATIONS

BREED

Coonhound

The CT study reveals bilateral obliteration of the horizontal external auditory meatuses by multiple small epithelial growths. The ear canals are severely stenotic secondary to the multiple growth formations. Multiple chronic inflammatory polyp formation is a primary differential diagnosis even though neoplasia such as adenoma, adenocarcinoma, ceruminous cell carcinoma, and other cannot be ruled out entirely. Final diagnosis will require sampling for histology.

SEX

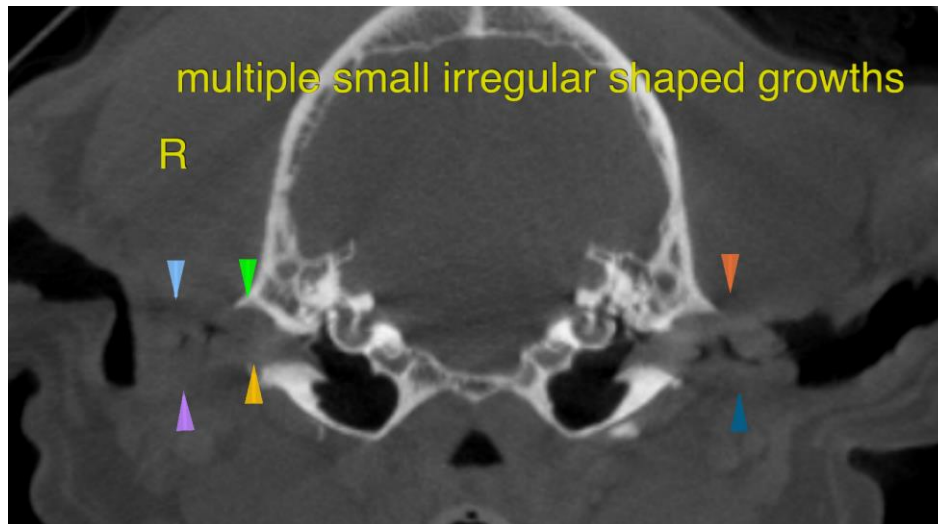
Neutered Male

AGE

7 Years

INTERPRETED BY

Nele Eley (Ondreka),
DVM Dr. med. vet.,
DipECVDI



HOSPITAL NAME

Mobile Pet Imaging

The information and recommendations provided are based on the images presented by the referring veterinarian. No evaluation can be communicated regarding pathology that was not visible in the image/video clips provided.

REFERRING VET

Meaux

Thank you for this referral. If the clinical or image interpretation does not parallel your findings or if I can be of any further assistance please contact me.

INVOICE

57179

Nele Eley (Ondreka), DVM, Dr. med. vet., DipECVDI
European Specialist in Veterinary Diagnostic Imaging, Cert. Radiology,
Senior lecturer University of Giessen/Germany, Veterinary Faculty, Department of Radiology.
Nele.Eley@sonopath.com

DATE

3-9-23