



PATIENT

Theo Poyton

PRESENTING CLINICAL SIGNS

Vomiting with bloody diarrhea for a couple days, owner offering leftovers
 Abnormal PE/Chem/CBC/UA Results: GGT High 30 range 0-14 U/I Total Bilirubin high 30 range 0-9 umol/l

SPECIES

Canine

RADIOGRAPHIC STUDY OF THE ABDOMEN

Right/left lateral and ventrodorsal views totaling 3 images available for review.

BREED

Pomeranian

RADIOGRAPHIC FINDINGS

The surrounding bony structures are within normal limits.

SEX

Male

No abnormalities of the extraabdominal soft tissues are noted. The abdominal wall is smooth and thin.

The serosal detail is maintained throughout the peritoneal and retroperitoneal space.

The liver is appropriate in position, size and presents uniform opacity.

AGE

3 Years

The splenic head is in the anticipated position and within normal limits for size and opacity. The splenic body and tail are considered normal for position, size, shape and opacity.

INTERPRETED BY

Nele Eley, DVM
 Dr. med. Vet. DipECVDI

Both kidneys are seen and present with normal size, shape, delineation and opacity. The urinary bladder is in its anticipated position. No radiopaque calculi are noted throughout the upper and lower urinary tract.

The stomach is empty except for a mild amount of gas.

HOSPITAL NAME

St. Catherine's Animal
 Hospital

The small intestinal loops are evenly distributed throughout the mid abdomen. No evidence of abnormal dilation, plication, or radiopaque foreign material is seen.

The colon is mostly empty and presents mild spasticity.

RADIOGRAPHIC DIAGNOSIS

REFERRING VET

Dr. Mena

- No radiographic signs of mechanical ileus.

INTERPRETATION OF THE FINDINGS & FURTHER RECOMMENDATIONS

The radiographic study reveals no direct signs of mechanical ileus. Consider functional ileus a likely potential. Further definition by means of abdominal ultrasound could be considered in case of persisting or deteriorating clinical signs.

INVOICE

50842

DATE

3-9-22



PATIENT

Theo Poyton

SPECIES

Canine

BREED

Pomeranian

SEX

Male

AGE

3 Years

INTERPRETED BY

Nele Eley, DVM
Dr. med. Vet. DipECVDI

HOSPITAL NAME

St. Catherine's Animal
Hospital

REFERRING VET

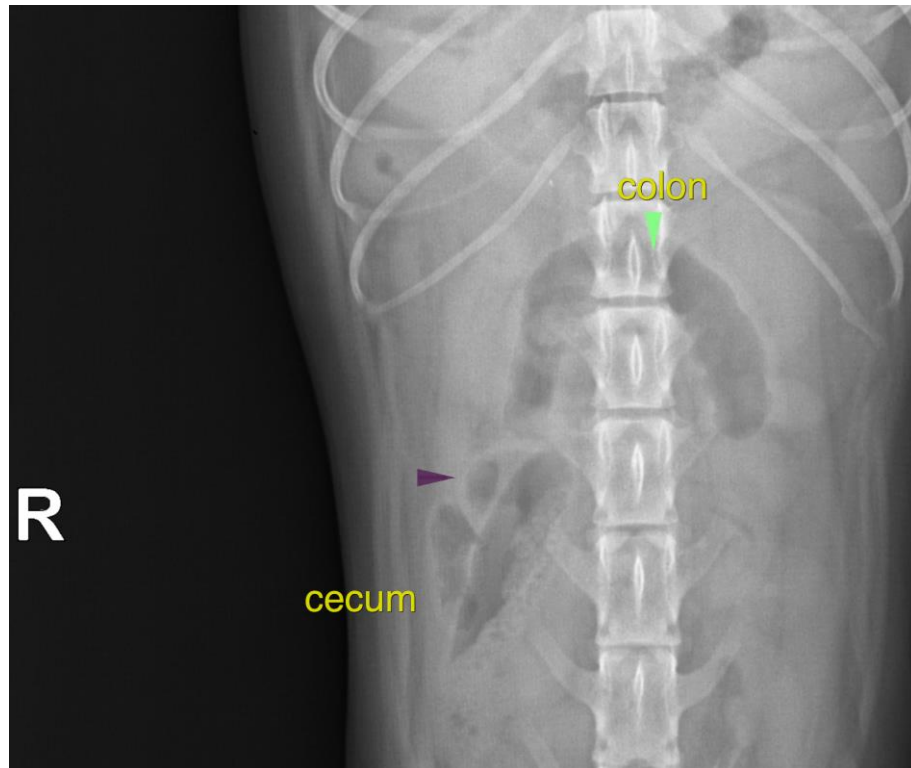
Dr. Mena

INVOICE

50842

DATE

3-9-22



The information and recommendations provided are based on the images presented by the referring veterinarian/sonographer. No evaluation can be communicated regarding pathology that was not visible in the image/video clips provided.

Thank you for this referral. If the clinical or image interpretation does not parallel your findings or if I can be of any further assistance please contact me.

Nele Eley, DVM, Dr. med. vet., DipECVDI
European Specialist in Veterinary Diagnostic Imaging, Cert. Radiology,
Senior lecturer University of Giessen, Germany, Veterinary Faculty, Department of Radiology
Nele.Eley@sonopath.com