



PATIENT

Koda Terreault

PRESENTING CLINICAL SIGNS

Koda has been favoring his hind end. He will take turns favoring the L and R hind. Favors the R hind more so. He still runs around and plays. His hind end will tremble and shake when just standing and after playing. He also will hunch his back up when rubbing above his hips and around his low back. He is laying around more when inside and he has started to get grumpy with the other dogs.

SPECIES

Canine

Abnormal PE/Chem/CBC/UA Results: FRONT LIMB MUSCLE ATROPHY. BILATERAL PAIN AND DECREASED FLEXION OF ELBOWS TL (MID-BACK) TENDERNESS HIPS EXTEND FINE, PROPRICEPTION FINE RT STIFLE: MEDIAL BUTTRESS, SWELLING, DRAWER. LT STIFLE: NORMAL

BREED

German Shepherd

RADIOGRAPHIC STUDY OF THE SPINE, SHOULDERS, ELBOWS, PELVIS, & STIFLES

22 images available for review.

SEX

MN

RADIOGRAPHIC FINDINGS

Shoulders

Extensive mineralization is seen adjacent to the right greater humeral tubercle coinciding with the position of the right supraspinatus tendon.

AGE

6 Years, 10 Months

The left shoulder present within normal limits.

INTERPRETED BY

Nele Eley, DVM
Dr. med. Vet. DipECVDI

Spine

Number, alignment, and anatomy of the cervical vertebrae present within normal limits.

T1/2, T4/5, T5/6, T11/12, T12/13, T13/L1, L1/2, L2/3, L3/4, L5/6, and L7/S1 spondyloses are seen.

HOSPITAL NAME

EI

Pelvis

The coxofemoral joints present no signs of dysplasia.

REFERRING VET

Leon Anderson, DVM

A mild amount of circumferential femoral head osteophytes are seen in the left and right coxofemoral joint as well as a mild amount of caudolateral curvilinear femoral neck osteophytes.

Osseous metaplasia of the right gluteus muscle is seen proximal of the greater trochanter of the femur.

INVOICE

50841

Stifles

Severe articular swelling of the right stifle with mild cranial thrust of the tibia and moderate periarticular osteophytes is present.

DATE

3-9-22

The left stifle presents within age related normal limits.



PATIENT

Elbow

Koda Terreault

Reduced opacity and blurred contour of the medial coronoid process are seen in both elbows. There is a large amount of periarticular osteophytes in both elbows.

SPECIES

Canine

- RADIOGRAPHIC DIAGNOSIS**
- Bilateral medial coronoid pathology with severe secondary osteoarthritis.
 - Mineralizing right supraspinatus tendinopathy.
 - Multiple thoracic and lumbar spondyloses as well as degenerative lumbosacral stenosis.
 - Moderate right stifle osteoarthritis with radiographic signs of cranial cruciate ligament failure.
 - Mild bilateral coxofemoral joint osteoarthritis and gluteus muscle metaplasia on the right side- both of questionable clinical significance.

BREED

German Shepherd

SEX

MN

AGE

6 Years, 10 Months

INTERPRETATION OF THE FINDINGS & FURTHER RECOMMENDATIONS

The main findings appear to be the medial coronoid pathology with severe secondary osteoarthritis in both elbows as well as signs of cranial cruciate ligament injury in the right stifle with moderate secondary osteoarthritis. There are also signs of degenerative lumbosacral stenosis which typically is associated with lumbosacral disc protrusion and compression of the cauda equina.

The mild bilateral coxofemoral joint osteoarthritis is unlikely to be of clinical significance.

INTERPRETED BY

Nele Eley, DVM
Dr. med. Vet. DipECVDI

HOSPITAL NAME

EI

REFERRING VET

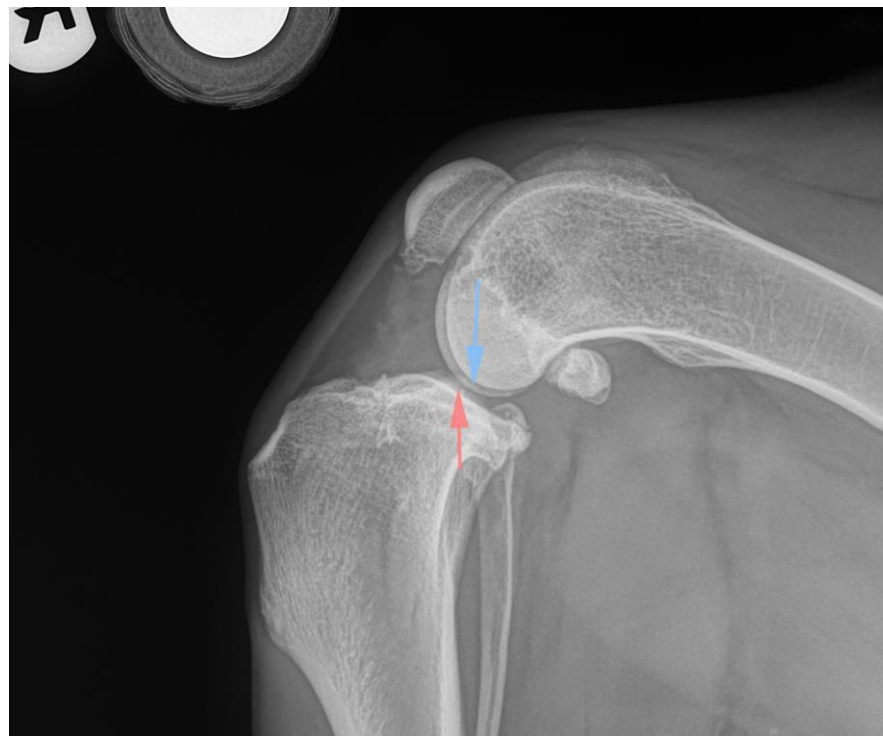
Leon Anderson, DVM

INVOICE

50841

DATE

3-9-22





PATIENT

Koda Terreault

The information and recommendations provided are based on the images presented by the referring veterinarian/sonographer. No evaluation can be communicated regarding pathology that was not visible in the image/video clips provided.

SPECIES

Canine

Thank you for this referral. If the clinical or image interpretation does not parallel your findings or if I can be of any further assistance please contact me.

BREED

German Shepherd

Nele Eley, DVM, Dr. med. vet., DipECVDI
European Specialist in Veterinary Diagnostic Imaging, Cert. Radiology,
Senior lecturer University of Giessen, Germany, Veterinary Faculty, Department of Radiology
Nele.Eley@sonopath.com

SEX

MN

AGE

6 Years, 10 Months

INTERPRETED BY

Nele Eley, DVM
Dr. med. Vet. DipECVDI

HOSPITAL NAME

EI

REFERRING VET

Leon Anderson, DVM

INVOICE

50841

DATE

3-9-22