



PATIENT

Benny Lihou

PRESENTING CLINICAL SIGNS

ate cooked pork bone 2 days ago , vomiting , watery diarrhea
Abnormal PE/Chem/CBC/UA Results: mild abdominal discomfort ,Blood work unremarkable ,

SPECIES

Canine

RADIOGRAPHIC STUDY OF THE ABDOMEN

Right lateral and ventrodorsal views totaling 2 images available for review.

BREED

Golden Doodle

RADIOGRAPHIC FINDINGS

The abdominal serosal detail is mildly reduced which is attributable to the patient's age and residuals of brown fat.

The stomach contains a mild amount of gas and fluid.

SEX

Male

The small intestinal loops are evenly distributed throughout the mid abdomen. There is no evidence of mineral opaque or other foreign material, plication, or abnormal dilation of the small intestine.

AGE

4 Months

A moderate amount of fecal matter and a mild amount of gas are seen within the cecum and colon. Mild spasticity of the transverse and cranial descending colon is noted.

RADIOGRAPHIC DIAGNOSIS

- Gastrointestinal maldigestion pattern - no evidence of mechanical ileus.

INTERPRETED BY

Nele Eley, DVM
Dr. med. Vet. DipECVDI

INTERPRETATION OF THE FINDINGS & FURTHER RECOMMENDATIONS

The radiographic study reveals no signs of mechanical ileus. The findings are compatible with the history of vomiting and diarrhea. No residuals of the bone or other foreign material are identified and conservative management with further clinical monitoring appears reasonable at this point.

HOSPITAL NAME

St. Catherine's Animal
Hospital

REFERRING VET

Dr. Masoud

INVOICE

50866

DATE

3-9-22



PATIENT

Benny Lihou

SPECIES

Canine

BREED

Golden Doodle

SEX

Male

AGE

4 Months

INTERPRETED BY

Nele Eley, DVM
Dr. med. Vet. DipECVDI

HOSPITAL NAME

St. Catherine's Animal
Hospital

REFERRING VET

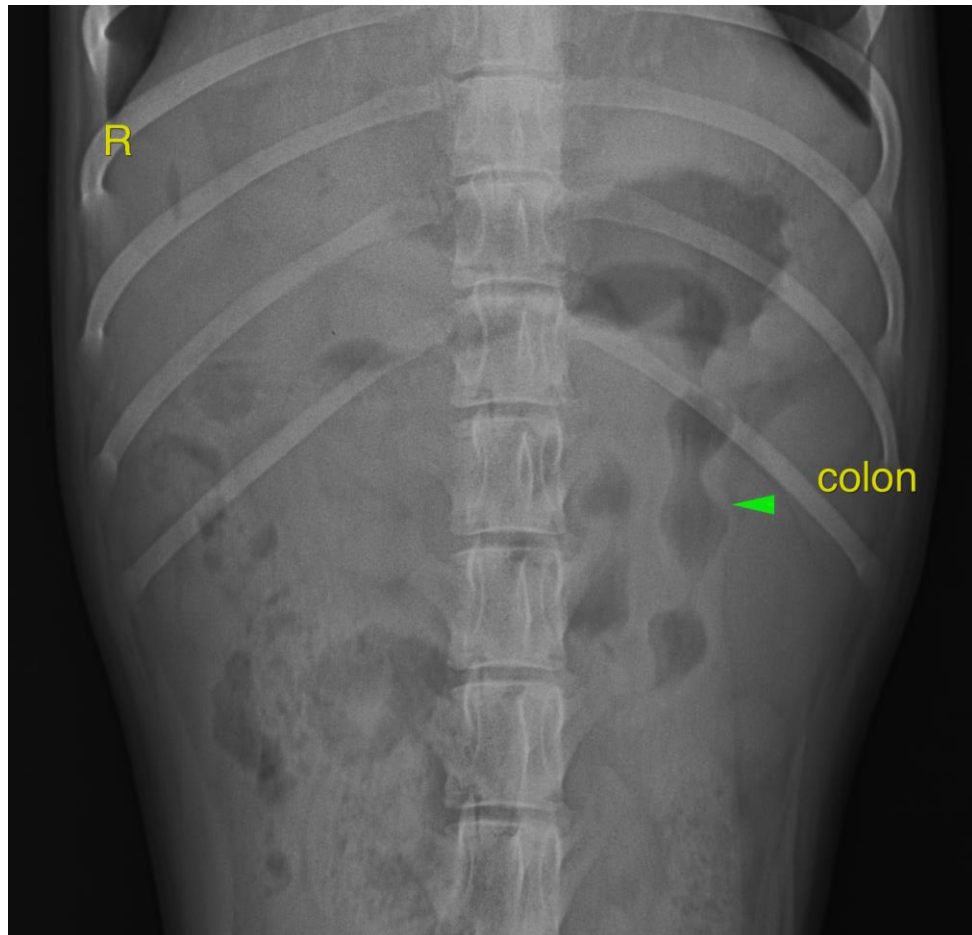
Dr. Masoud

INVOICE

50866

DATE

3-9-22



The information and recommendations provided are based on the images presented by the referring veterinarian/sonographer. No evaluation can be communicated regarding pathology that was not visible in the image/video clips provided.

Thank you for this referral. If the clinical or image interpretation does not parallel your findings or if I can be of any further assistance please contact me.

Nele Eley, DVM, Dr. med. vet., DipECVDI
European Specialist in Veterinary Diagnostic Imaging, Cert. Radiology,
Senior lecturer University of Giessen, Germany, Veterinary Faculty, Department of Radiology
Nele.Eley@sonopath.com