

**PATIENT**

Sugar Plum Pirock-Smith

PRESENTING CLINICAL SIGNS

6+ month history of multi limb pain; prior rads indicate bilateral elbow OA and right knee effusion
Exam: Right knee pain + cr drawer; left hip pain

SPECIES

Canine

ULTRASONOGRAPHIC FINDINGS**Right Stifle**

Moderate effusion is seen within the supra- and infra-patellar recesses of the right stifle joint. The cranial cruciate ligament presents as an echogenic stump surrounded by a hypoechoic halo at the intercondylar eminence of the tibia. Regional fat-pad heterogeneity is seen. The medial meniscus is in situ, smoothly delineated, and presents no evidence of injury.

BREED

Corgi-mix

Left Stifle**SEX**

FS

No abnormal effusion is seen within the supra- and infra patellar area. There is no evidence of synovial or capsular thickening or proliferation. The cranial cruciate ligament appears to be continuous and well-delineated, no deviation from normal echoarchitecture is noted. Lateral and medial menisci are within their anticipated positions and align well below the bone surfaces, meniscal surfaces are even and smooth. The echotexture is hypo echoic and uniform. The joint margins are smooth, no osteophytes are seen. The infra patellar fat pad present, the expected echo architecture.

AGE

7 Years

ULTRASONOGRAPHIC DIAGNOSIS

- Osteoarthritis of the right stifle joint with cranial cruciate ligament pathology.

INTERPRETED BYNele Eley, DVM
Dr. med. Vet. DipECVDI**INTERPRETATION OF THE FINDINGS & FURTHER RECOMMENDATIONS**

The ultrasonographic findings of the right stifle are compatible with complete rupture of the cranial cruciate ligament. Concurrent synovialitis and effusion is seen. At this point, there is no evidence of medial meniscopathy. Consider surgical intervention in order to address the biomechanical instability and prevent further damage to the articular structures.

HOSPITAL NAMEColorado Animal
Specialty &
Emergency**REFERRING VET**

James Gaynor

INVOICE

57154

DATE

3-8-23



PATIENT

Sugar Plum Pirock-Smith

SPECIES

Canine

BREED

Corgi-mix

SEX

FS

AGE

7 Years

INTERPRETED BY

Nele Eley, DVM
Dr. med. Vet. DipECVDI

HOSPITAL NAME

Colorado Animal
Specialty &
Emergency

REFERRING VET

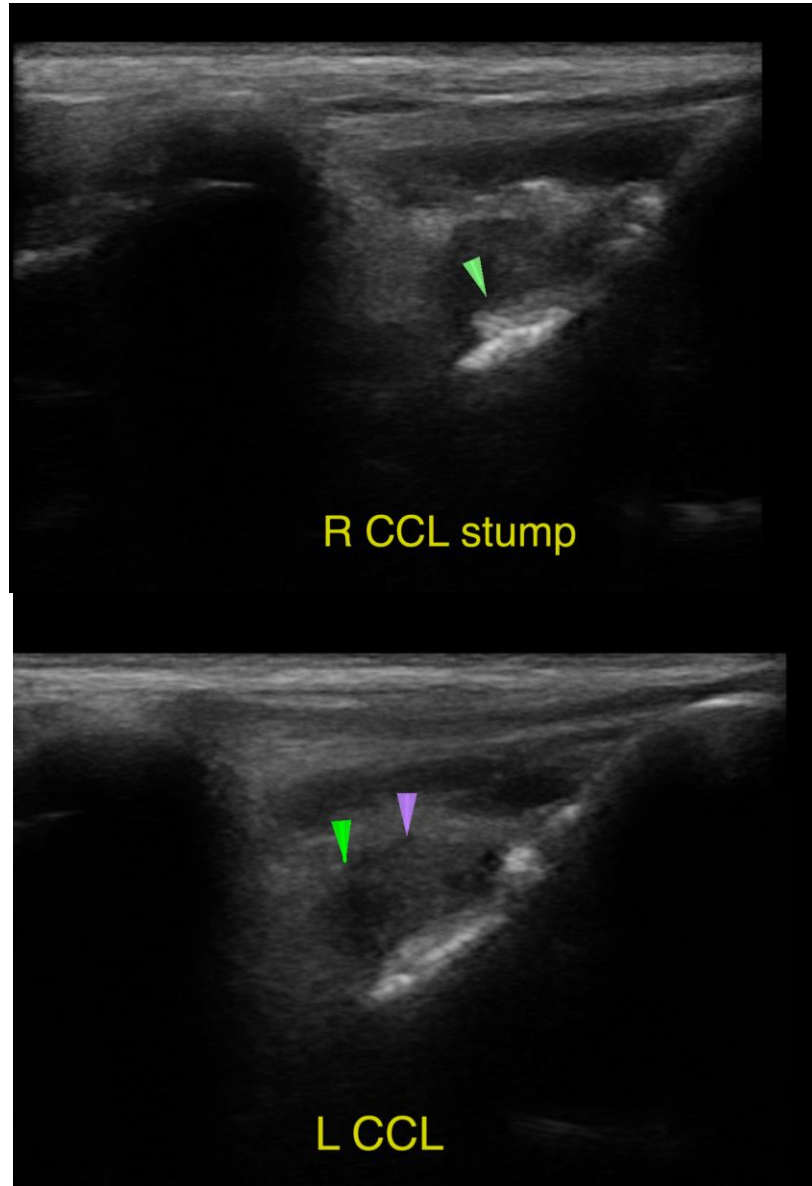
James Gaynor

INVOICE

57154

DATE

3-8-23



The information and recommendations provided are based on the images presented by the referring veterinarian/sonographer. No evaluation can be communicated regarding pathology that was not visible in the image/video clips provided.

Thank you for this referral. If the clinical or image interpretation does not parallel your findings or if I can be of any further assistance please contact me.

Nele Eley, DVM, Dr. med. vet., DipECVDI
European Specialist in Veterinary Diagnostic Imaging, Cert. Radiology,
Senior lecturer University of Giessen, Germany, Veterinary Faculty, Department of Radiology
Nele.Eley@sonopath.com