



**PATIENT**

Scout Lazaroff

**PRESENTING CLINICAL SIGNS**

Dog limps and favours the left rear leg, Worse after exercise  
Abnormal PE/Chem/CBC/UA Results: Has a stable joint, No Cr Drawer, No CTT, Has a medial buttress sign. Joint effusion left knee.

**SPECIES**

Canine

**ULTRASONOGRAPHIC FINDINGS**

**Left Stifle**

**BREED**

Lab

A large amount of effusion is present in the supra- and infra-patellar recesses of the left stifle joint. Moderate swelling of the stifle joint's synovium is seen. The cranial cruciate ligament is continuous yet presents slight overall thickening with ill-defined margins and internal heterogeneity. The lateral and medial meniscus are in situ, smoothly delineated, and present uniform internal echoarchitecture.

**SEX**

MN

**ULTRASONOGRAPHIC DIAGNOSIS**

- Synovialitis, effusion, and suspect cruciate ligament injury in the left stifle joint.

**AGE**

2 Years, 1 Month

**INTERPRETATION OF THE FINDINGS & FURTHER RECOMMENDATIONS**

The ultrasonographic findings support the presence of partial rupture of the left cranial cruciate ligament. I suspect that most of the fibers are maintained and that this represents an early stage of partial rupture of the left cranial cruciate ligament, which is likely to progress to biomechanical loss of function. At this point, there is no ultrasonographic evidence of meniscopathy.

**INTERPRETED BY**

Nele Eley, DVM  
Dr. med. Vet. DipECVDI

**HOSPITAL NAME**

Westview Veterinary  
Hospital

**REFERRING VET**

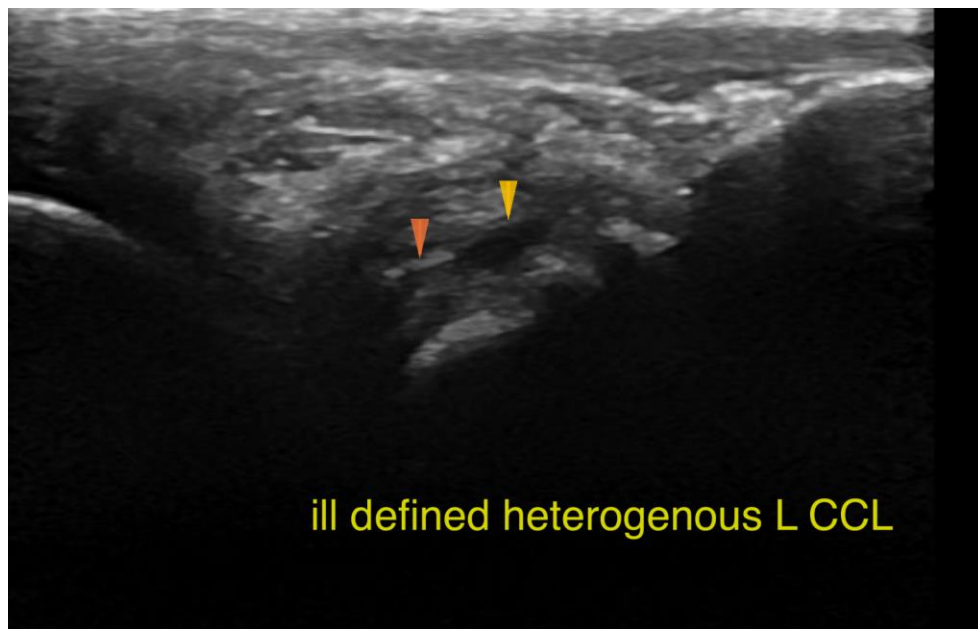
Dr. Brian Barnes

**INVOICE**

57156

**DATE**

3-8-23





**PATIENT**

Scout Lazaroff

The information and recommendations provided are based on the images presented by the referring veterinarian/sonographer. No evaluation can be communicated regarding pathology that was not visible in the image/video clips provided.

**SPECIES**

Canine

Thank you for this referral. If the clinical or image interpretation does not parallel your findings or if I can be of any further assistance please contact me.

**Nele Eley**, DVM, Dr. med. vet., DipECVDI  
European Specialist in Veterinary Diagnostic Imaging, Cert. Radiology,  
Senior lecturer University of Giessen, Germany, Veterinary Faculty, Department of Radiology  
Nele.Eley@sonopath.com

**BREED**

Lab

**SEX**

MN

**AGE**

2 Years, 1 Month

**INTERPRETED BY**

Nele Eley, DVM  
Dr. med. Vet. DipECVDI

**HOSPITAL NAME**

Westview Veterinary  
Hospital

**REFERRING VET**

Dr. Brian Barnes

**INVOICE**

57156

**DATE**

3-8-23