



PATIENT

Toree Cooper

PRESENTING CLINICAL SIGNS

Dog has hx of arthritis, takes deracoxib, has gotten more painful and restless lately. Has mass on left hind leg around metatarsus that came up about 2 months ago, it is firm and painful on palpation. Also started having seizures the past several months, controlled on keppra.

SPECIES

Abnormal PE/Chem/CBC/UA Results: CBC/Chem/T4 pending, lung rads showed no signs of metastasis. Normal BW 6 months ago

Canine

RADIOGRAPHIC STUDY OF THE LEFT TARSUS

BREED

Mediolateral, dorsoplantar, and oblique views of the left tarsus totaling 9 images available for review.

Labrador

RADIOGRAPHIC FINDINGS

SEX

An approximately 3.0 x 1.5 cm sized semi-ovoid soft tissue opaque mass is seen plantar and lateral of the left proximal metatarsus. There is a large amount of smoothly delineated new bone in the plantar contour of the 5th metatarsal bone with proximal extension. A mild amount of smooth new bone is noted in the plantar and lateral contour of the 4th tarsal bone as well.

FS

AGE

A rounded isolated bony structure of 1.5mm is seen superimposed onto the distal aspect of the soft tissue mass.

10

No evidence of intertarsal or tarsocrural osteoarthritis or articular swelling is seen.

INTERPRETED BY

Nele Eley, DVM
Dr. med. Vet. DipECVDI

RADIOGRAPHIC DIAGNOSIS

- Soft tissue mass plantar of the 5th left metatarsal bone with bone production in the 5th metatarsal bone and 4th tarsal bone and no evidence of aggressive osteolytic changes.

HOSPITAL NAME

Harvest Hills
Veterinary Hospital

INTERPRETATION OF THE FINDINGS & FURTHER RECOMMENDATIONS

Differential diagnosis includes soft tissue neoplasia, organizing hematoma, as well as chronic avulsion injury of the short fibularis head and plantar ligament which both attach to the base of the 5th metatarsal bone. Clinical correlation is required. Consider tissue sampling by means of incisional biopsy for further histologic workup.

REFERRING VET

Reser

INVOICE

50811

DATE

3-8-22



PATIENT

Toree Cooper

SPECIES

Canine

BREED

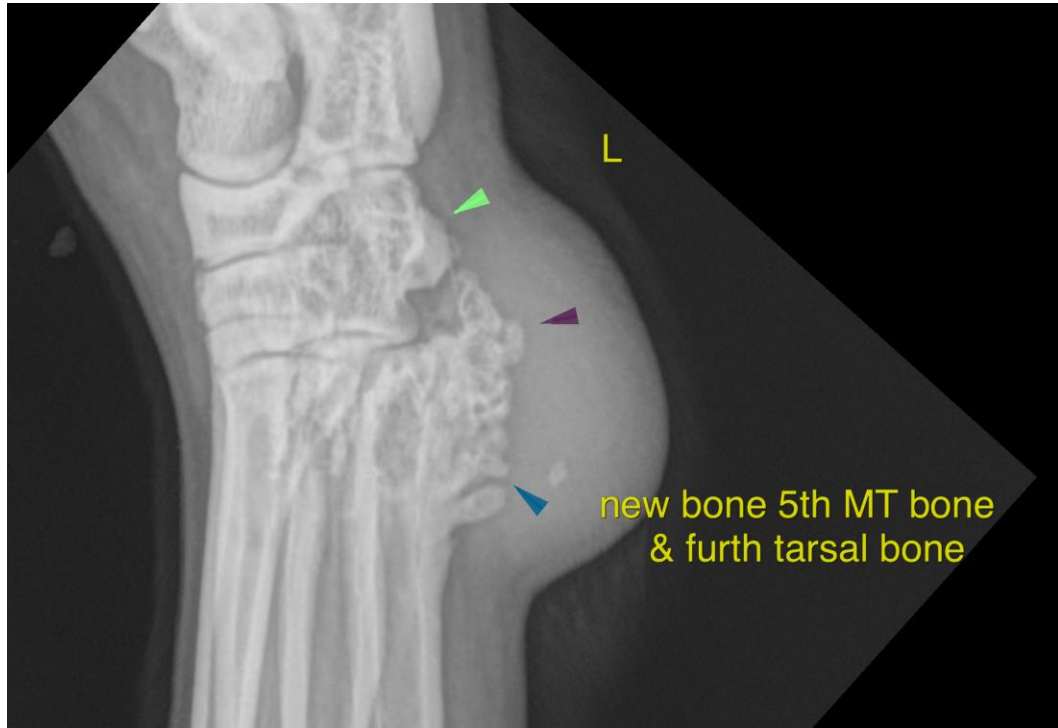
Labrador

SEX

FS

AGE

10



INTERPRETED BY

Nele Eley, DVM
Dr. med. Vet. DipECVDI

The information and recommendations provided are based on the images presented by the referring veterinarian/sonographer. No evaluation can be communicated regarding pathology that was not visible in the image/video clips provided.

HOSPITAL NAME

Harvest Hills
Veterinary Hospital

Thank you for this referral. If the clinical or image interpretation does not parallel your findings or if I can be of any further assistance please contact me.

Nele Eley, DVM, Dr. med. vet., DipECVDI
European Specialist in Veterinary Diagnostic Imaging, Cert. Radiology,
Senior lecturer University of Giessen, Germany, Veterinary Faculty, Department of Radiology
Nele.Eley@sonopath.com

REFERRING VET

Reser

INVOICE

50811

DATE

3-8-22