



PATIENT

Rudy Leon

PRESENTING CLINICAL SIGNS

Rudy presented for mass near right shoulder/neck/back area. O states it was first noticed about 4 months ago and has grown quickly. FNA was inconclusive. Owners elected to just do surgical excision without the benefit of a CT or Ultrasound for Staging Owner was dropped off for surgical excision Upon new examination mild pitting edema was present along the LFL and LHL Pre-op blood work was normal Called owner Aborted surgical excision for today and recommend CT scan for staging and possible cause of edema

SPECIES

Canine

COMPUTED TOMOGRAPHIC STUDY OF THE THORAX & ABDOMEN

BREED

Pitbull Mix

Post-contrast studies available for review.

Assessment of the studies is limited due to the presence of multiple beam hardening and motion related streak artifacts.

SEX

MN

COMPUTED TOMOGRAPHIC FINDINGS

Abdomen

Moderate degenerative lumbosacral stenosis is seen.

AGE

9 Years

There is a large intermuscular lipoma in the caudal right thigh between the biceps femoris and semitendinosus muscles.

INTERPRETED BY

Nele Eley, DVM
Dr. med. Vet. DipECVDI

The coxofemoral joints and stifle joints present within age related normal limits.

The popliteal lymph nodes and subinguinal lymph nodes present within normal limits.

No significant soft tissue swelling of the right and left hind limb is noted.

HOSPITAL NAME

Animal Surgical
Center

The abdominal lymph nodes present within normal limits.

No evidence of peritoneal effusion is seen.

A pyelogram of both kidneys is seen as this is a late post-contrast study. The pathways of the ureters present within normal limits.

REFERRING VET

Dr. R. Lombardi

Mild generalized enlargement of the spleen is noted and considered secondary to hypotension under general anesthesia.

INVOICE

50846

A small mineral attenuating polygonal structure is seen in the transverse colon in the cranial abdomen.

The liver and gallbladder present within the expected limits.

DATE

3-8-22

Thorax

There is no evidence of pulmonary masses or nodules.

The mediastinal lymph nodes present within normal limits.



PATIENT

A large soft tissue attenuating mass in the right cranial and dorsal thoracic wall is partially included in the collimated field of view.

Rudy Leon

COMPUTED TOMOGRAPHIC DIAGNOSIS

SPECIES

Canine

- Soft tissue mass in the craniodorsal right thoracic wall meeting neoplastic criteria.
- Intermuscular lipoma proximal and caudal right thigh.
- No evidence of pulmonary metastatic disease.
- No evidence of mediastinal lymphadenomegaly or other mediastinal mass effect.
- Normal age related abdomen.
- Degenerative lumbosacral stenosis.

BREED

Pitbull Mix

INTERPRETATION OF THE FINDINGS & FURTHER RECOMMENDATIONS

SEX

MN

The soft tissue mass in the right cranial and dorsal thoracic wall is incompletely included in the collimated field of view. Soft tissue sarcoma is considered most likely. There is no evidence of thoracic extension.

The thorax and mediastinal structures present within the expected limits.

AGE

9 Years

No evidence of abdominal pathology is noted.

The visible peripheral lymph nodes present within normal limits.

INTERPRETED BY

Nele Eley, DVM
Dr. med. Vet. DipECVDI

HOSPITAL NAME

Animal Surgical
Center

REFERRING VET

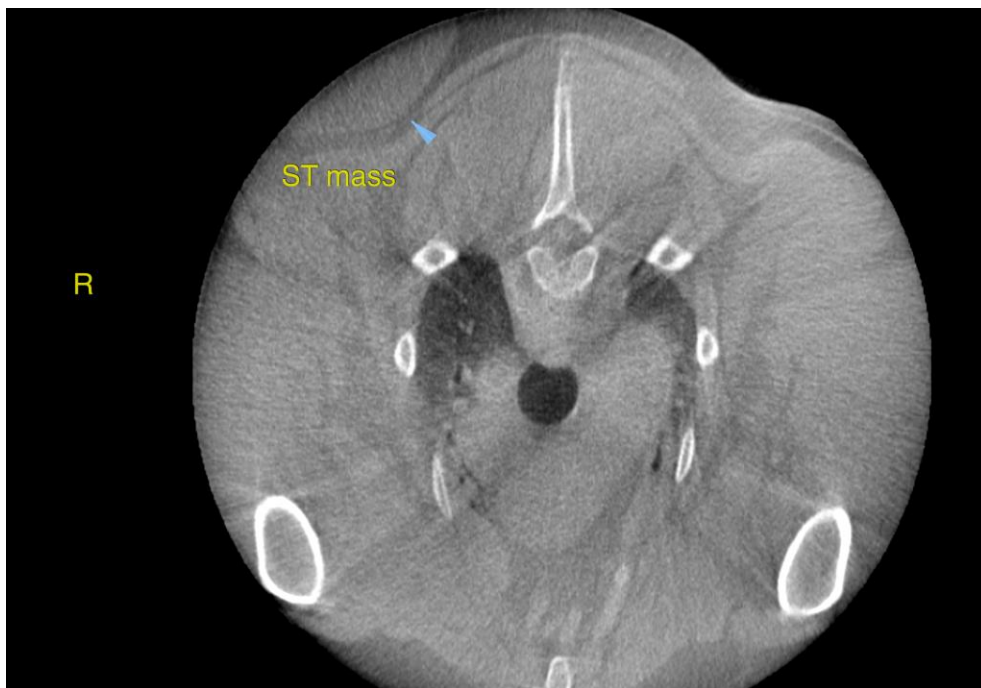
Dr. R. Lombardi

INVOICE

50846

DATE

3-8-22





PATIENT

Rudy Leon

The information and recommendations provided are based on the images presented by the referring veterinarian/sonographer. No evaluation can be communicated regarding pathology that was not visible in the image/video clips provided.

Thank you for this referral. If the clinical or image interpretation does not parallel your findings or if I can be of any further assistance please contact me.

SPECIES

Canine

Nele Eley, DVM, Dr. med. vet., DipECVDI
European Specialist in Veterinary Diagnostic Imaging, Cert. Radiology,
Senior lecturer University of Giessen, Germany, Veterinary Faculty, Department of Radiology
Nele.Eley@sonopath.com

BREED

Pitbull Mix

SEX

MN

AGE

9 Years

INTERPRETED BY

Nele Eley, DVM
Dr. med. Vet. DipECVDI

HOSPITAL NAME

Animal Surgical
Center

REFERRING VET

Dr. R. Lombardi

INVOICE

50846

DATE

3-8-22