

**PATIENT**

Ricky David

SPECIES

Feline

BREEDDomestic Medium
Hair**SEX**

Neutered Male

AGE

14 Years, 4 Months

INTERPRETED BYNele Eley, DVM
Dr. med. Vet. DipECVDI**HOSPITAL NAME**Ahwatukee Commons
Veterinary Hospital**REFERRING VET**

Linda Elliott, D.V.M.

INVOICE

50808

DATE

3-8-22

PRESENTING CLINICAL SIGNS

Pt has history of asthma and has a regular cough per owner. Pt presents with sneezing that originally started and stopped around Christmas, but started back up 3 weeks ago per Owner. Owner also states that Pt sneezed blood on Friday and Saturday - a total of three times. O also states that Pt has been eating less than normal for the past 3 weeks, but is drinking water okay. Owner states that P has not groomed himself since around Christmas. Nasal flushed preformed via Dr. Elliott, culture & sensitivity - sent, pending results.

RADIOGRAPHIC STUDY OF THE HEAD

Intubated and non-intubated patient - dorsoventral, lateral, oblique, and open mouth dorsoventral views totaling 5 images available for review.

RADIOGRAPHIC FINDINGS

An overall increase in soft tissue opacity of the nasal cavities is noted accentuating their rostral and mid third. No overt conchae destruction and no evidence of aggressive osteolysis is seen. However, the folding and recognizability of the nasal turbinates appear to be reduced.

The frontal sinuses appear to be aerated and within normal limits.

RADIOGRAPHIC DIAGNOSIS

- Suspect bilateral rhinopathy with increase soft tissue within the nasal cavities.

INTERPRETATION OF THE FINDINGS & FURTHER RECOMMENDATIONS

Increased soft tissue opacity is seen within both nasal cavities accentuating their rostral and mid third. Differential diagnosis includes nondestructive and destructive rhinitis as well as early soft tissue neoplasia. CT as well as rhinoscopy and sampling would be ideal for further definition.



PATIENT

Ricky David

SPECIES

Feline

BREED

Domestic Medium
Hair

SEX

Neutered Male

AGE

14 Years, 4 Months

INTERPRETED BY

Nele Eley, DVM
Dr. med. Vet. DipECVDI

HOSPITAL NAME

Ahwatukee Commons
Veterinary Hospital

REFERRING VET

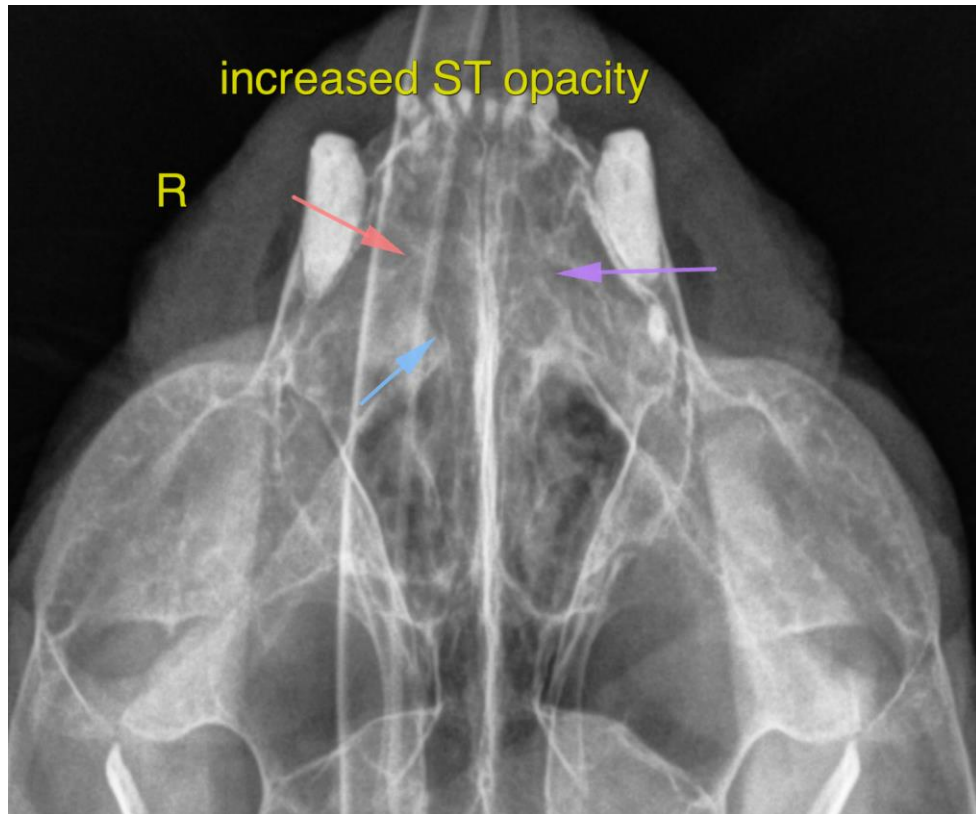
Linda Elliott, D.V.M.

INVOICE

50808

DATE

3-8-22



The information and recommendations provided are based on the images presented by the referring veterinarian/sonographer. No evaluation can be communicated regarding pathology that was not visible in the image/video clips provided.

Thank you for this referral. If the clinical or image interpretation does not parallel your findings or if I can be of any further assistance please contact me.

Nele Eley, DVM, Dr. med. vet., DipECVDI
European Specialist in Veterinary Diagnostic Imaging, Cert. Radiology,
Senior lecturer University of Giessen, Germany, Veterinary Faculty, Department of Radiology
Nele.Eley@sonopath.com