



**PATIENT PRESENTING CLINICAL SIGNS**

Lio Ruggiero History of two cystotomies for urate stones. Low urea, microcytosis. Marked elevated pre and post prandial bile acids.

**SPECIES COMPUTED TOMOGRAPHIC STUDY OF THE ABDOMEN**

Canine CT angiogram of the abdomen available for review.

**COMPUTED TOMOGRAPHIC FINDINGS**

**BREED**  
Shih Tzu X The patient appears to be an intact male.

The serosal fat presents normal attenuation behavior. There is no evidence of peritoneal effusion or peritonitis.

**SEX**  
MN Both kidneys present within normal limits for size, shape and organ architecture. After contrast administration a bilaterally symmetric and uniform nephro- and pyelogram is noted.

The adrenal glands are within normal limits for size, shape and organ architecture.

**AGE**  
3 Years The spleen presents with normal shape, even surface, uniformly attenuating parenchyma and homogeneous contrast enhancement, unremarkable.

**INTERPRETED BY**  
Nele Eley, DVM  
Dr. med. Vet. DipECVDI A single extrahepatic portosystemic shunt is seen emerging from the gastroduodenal vein and coursing towards the left of the midline in a long loop to feed into the caudal vena cava from the left side level with the cranial pole of the right kidney. Maximum shunt diameter is 7.5mm. Diameter of the shunt at the entrance into the caudal vena cava is 3mm.

The liver is small in size. Reduced intrahepatic portal vein branching is noted. The extrahepatic portal vein diameter decreases abruptly cranial of the shunt origin. Reduced portal vein/aorta ratio is noted.

**HOSPITAL NAME**  
Animal Health Partners The pancreas is evenly contoured, the pancreatic parenchyma is homogeneous and presents uniform contrast enhancement.

**REFERRING VET**  
Dr. Westgarth The position, delineation, wall and content of the gastrointestinal tract are considered within normal limits throughout.

The bony and surrounding soft tissue structures reveal no abnormalities.

**COMPUTED TOMOGRAPHIC DIAGNOSIS**

- INVOICE**  
50806
- Single congenital extrahepatic portosystemic shunt of the right gastric vein type.
  - Microhepatica.

**INTERPRETATION OF THE FINDINGS & FURTHER RECOMMENDATIONS**

**DATE**  
3-8-22 The CT study confirms the presence of a single congenital extrahepatic portosystemic shunt of the right gastric vein type. Consider shunt closure by means of a slowly attenuating technique as well as dietetic and medical management as indicated.



**PATIENT**

Lio Ruggiero

**SPECIES**

Canine

**BREED**

Shih Tzu X

**SEX**

MN

**AGE**

3 Years

**INTERPRETED BY**

Nele Eley, DVM  
Dr. med. Vet. DipECVDI

**HOSPITAL NAME**

Animal Health  
Partners

**REFERRING VET**

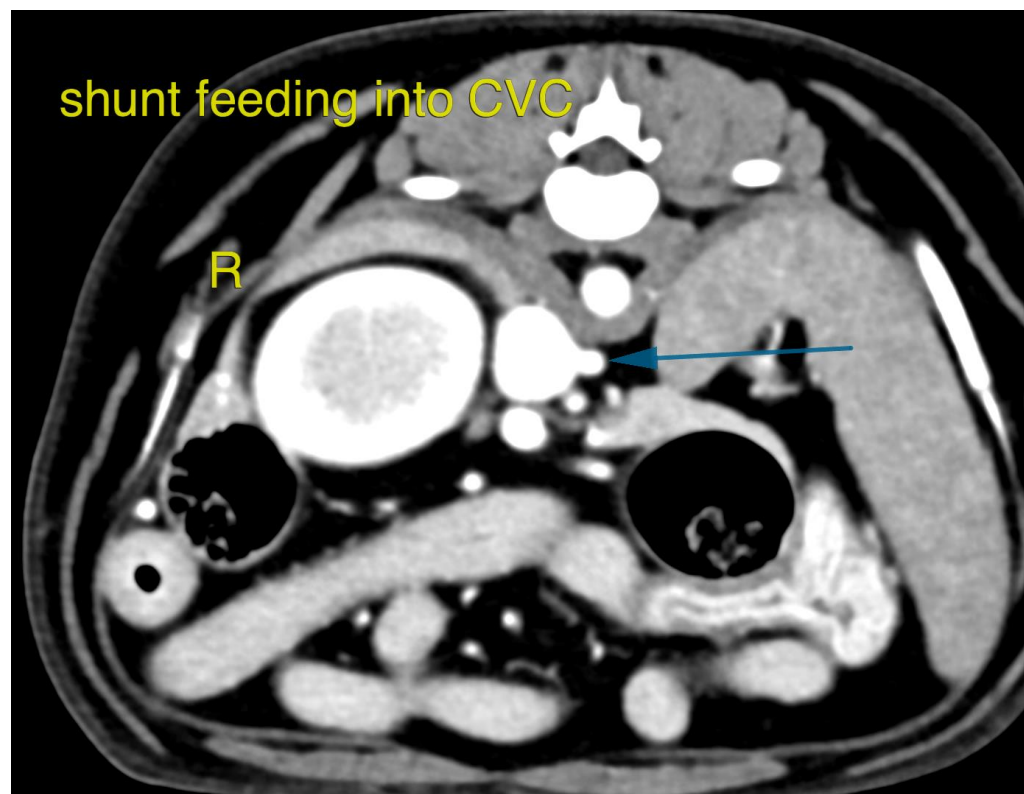
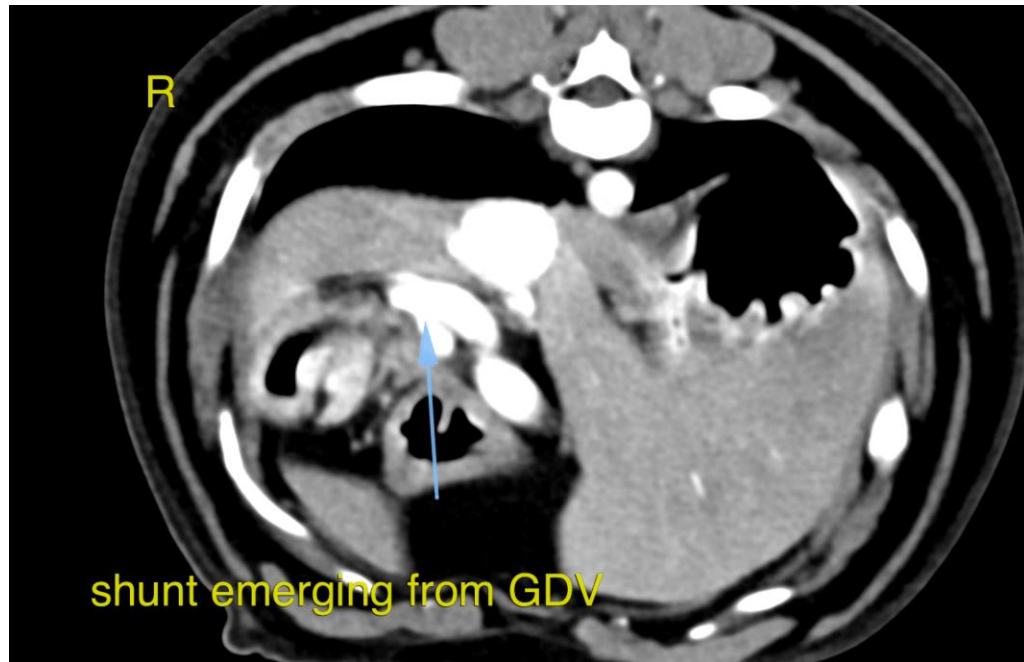
Dr. Westgarth

**INVOICE**

50806

**DATE**

3-8-22





**PATIENT**

Lio Ruggiero

**SPECIES**

Canine

**BREED**

Shih Tzu X

**SEX**

MN

**AGE**

3 Years

**INTERPRETED BY**

Nele Eley, DVM  
Dr. med. Vet. DipECVDI

**HOSPITAL NAME**

Animal Health  
Partners

**REFERRING VET**

Dr. Westgarth

**INVOICE**

50806

**DATE**

3-8-22

The information and recommendations provided are based on the images presented by the referring veterinarian/sonographer. No evaluation can be communicated regarding pathology that was not visible in the image/video clips provided.

Thank you for this referral. If the clinical or image interpretation does not parallel your findings or if I can be of any further assistance please contact me.

**Nele Eley**, DVM, Dr. med. vet., DipECVDI  
European Specialist in Veterinary Diagnostic Imaging, Cert. Radiology,  
Senior lecturer University of Giessen, Germany, Veterinary Faculty, Department of Radiology  
Nele.Eley@sonopath.com