



PATIENT

Kaiser Jones

PRESENTING CLINICAL SIGNS

LH CCL injury. Suspect partial unstable to complete tear.
Abnormal PE/Chem/CBC/UA Results: N/A

SPECIES

Canine

ULTRASONOGRAPHIC FINDINGS

Left Stifle

Moderate effusion is seen within the infrapatellar recess of the left stifle joint. Moderate swelling of the visible synovium is noted. The cranial cruciate ligament presents thin and ill-defined with multifocal increase in internal echogenicity. Part of the fibers appear to be continuous. Mild smooth new bone formation is seen at the displayed periarticular margins.

BREED

German Shepard

ULTRASONOGRAPHIC DIAGNOSIS

SEX

- Synovialitis and effusion of the left stifle joint with cruciate ligament injury.

MN

INTERPRETATION OF THE FINDINGS & FURTHER RECOMMENDATIONS

AGE

6 Years

The ultrasonographic findings support the presence of partial rupture of the left cranial cruciate ligament. The findings are likely to translate in full biomechanical failure of the ligament despite the presence of a small amount of continuous fibers. Surgical intervention should be considered in order to address the presumed biomechanical instability and prevent damage to the articular structures including the menisci.

INTERPRETED BY

Nele Eley, DVM
Dr. med. Vet. DipECVDI

HOSPITAL NAME

Foxfield Veterinary
Services

REFERRING VET

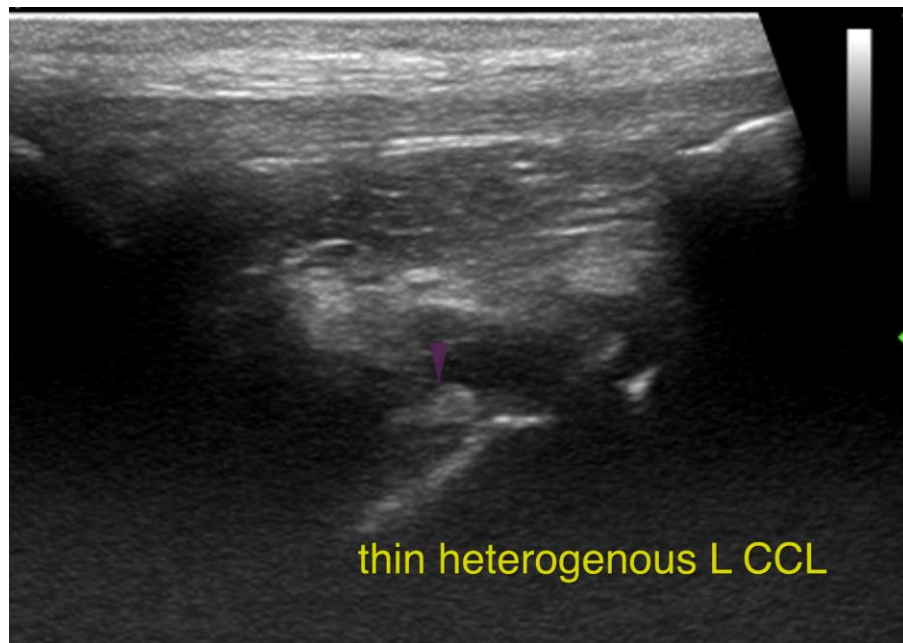
A, Rodriguez

INVOICE

57113

DATE

3-7-23





PATIENT

Kaiser Jones

The information and recommendations provided are based on the images presented by the referring veterinarian/sonographer. No evaluation can be communicated regarding pathology that was not visible in the image/video clips provided.

Thank you for this referral. If the clinical or image interpretation does not parallel your findings or if I can be of any further assistance please contact me.

SPECIES

Canine

Nele Eley, DVM, Dr. med. vet., DipECVDI
European Specialist in Veterinary Diagnostic Imaging, Cert. Radiology,
Senior lecturer University of Giessen, Germany, Veterinary Faculty, Department of Radiology
Nele.Eley@sonopath.com

BREED

German Shepard

SEX

MN

AGE

6 Years

INTERPRETED BY

Nele Eley, DVM
Dr. med. Vet. DipECVDI

HOSPITAL NAME

Foxfield Veterinary
Services

REFERRING VET

A, Rodriguez

INVOICE

57113

DATE

3-7-23