



PATIENT

Jasper Gill

PRESENTING CLINICAL SIGNS

Jasper was diagnosed in December of 2022 with a grade 3 -4/6 heart murmur. He is asymptomatic and is not currently on any medications.
Abnormal PE/Chem/CBC/UA Results: Grade 2/6 heart murmur on exam today.

SPECIES

Canine

RADIOGRAPHIC STUDY OF THE THORAX

Right/left lateral and dorsoventral views of the thorax totaling 3 images available for review in jpeg format.

BREED

Maltese X

Only jpg images were submitted. The transformation from DICOM to jpg only allows for limited manipulation of the image. For the best possible results, we suggest submitting DICOM images in the future. Please do not hesitate to contact us should you need any help with the submission process.

SEX

Neutered Male

RADIOGRAPHIC FINDINGS

A fat opaque small ovoid subcutaneous structure is seen ventral to the xiphoid.

AGE

13.5 Years

Marked redundancy of the dorsal tracheal ligament is noted throughout the cervical trachea.

There is mild esophageal aerophagia.

The lungs are deeply inflated. No evidence of a vascular lung pattern or cardiogenic pulmonary edema is seen.

INTERPRETED BY

Nele Eley, DVM
Dr. med. Vet. DipECVDI

The cardiac silhouette presents within normal limits. There is no evidence of overall enlargement or specific chamber enlargement noted. The left atrium presents within normal limits. The vertebral heart score is 10.

HOSPITAL NAME

Lacombe Veterinary
Centre

Gastric aerophagia is noted.

There appears to be a soft tissue opaque structure within the stomach which is only partially included in the collimated field of view.

REFERRING VET

Dr. Cindy Nowle

RADIOGRAPHIC DIAGNOSIS

- Normal radiographic presentation of the cardiovascular structures with no evidence of volume overload or congestive heart failure. No radiographic evidence of left atrial or left ventricular enlargement.
- Redundant tracheal membrane.
- Aerophagia.
- Suspect lipoma ventral to the xiphoid, differential diagnosis: ventral hernia.
- Questionable foreign object within the stomach.

INVOICE

57111

DATE

3-7-23

INTERPRETATION OF THE FINDINGS & FURTHER RECOMMENDATIONS

The radiographic presentation of the cardiac silhouette is within normal limits. There is no evidence of cardiomegaly, left atrial, or left ventricular enlargement and no evidence of congestive heart failure.



PATIENT

Jasper Gill

According to the EPIC study and ACVIM criteria, this would fall under stage B1 mitral valve disease and the use of Pimobendan (Vetmedin) is recommended with stage B2 valvular disease which there is no evidence of for in this radiographic study at this point.

SPECIES

Canine

The redundant tracheal membrane can be an incidental finding. It can be associated with dynamic tracheal disease. Clinical correlation required.

BREED

Maltese X

SEX

Neutered Male

AGE

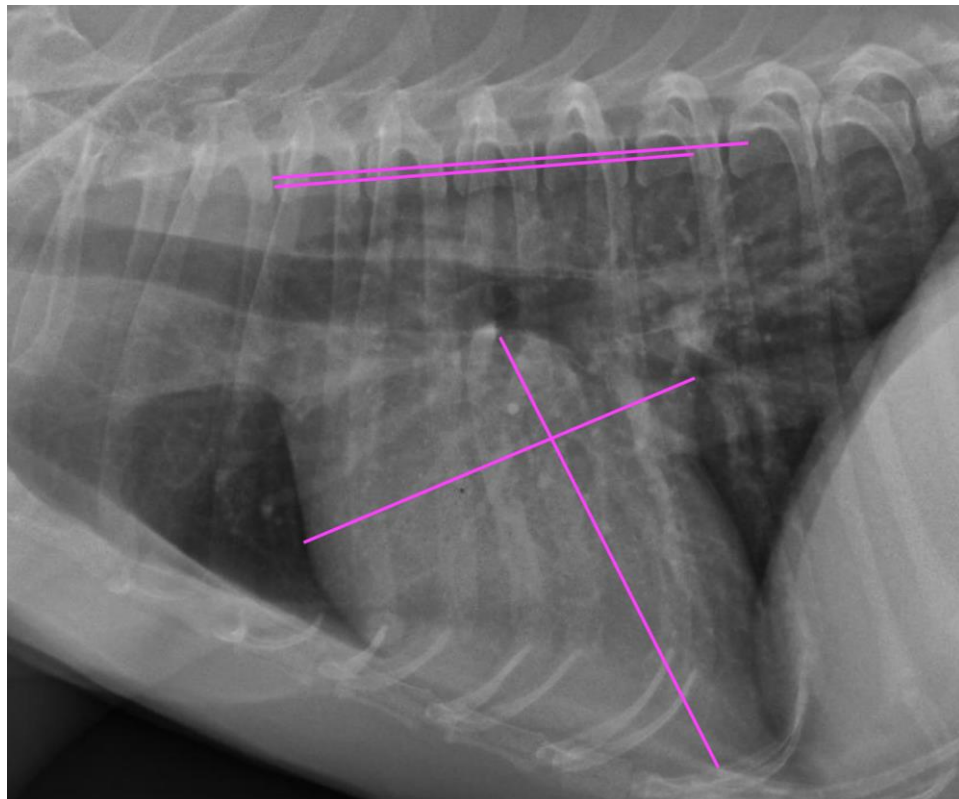
13.5 Years

INTERPRETED BY

Nele Eley, DVM
Dr. med. Vet. DipECVDI

HOSPITAL NAME

Lacombe Veterinary
Centre



REFERRING VET

Dr. Cindy Nowle

The information and recommendations provided are based on the images presented by the referring veterinarian/sonographer. No evaluation can be communicated regarding pathology that was not visible in the image/video clips provided.

INVOICE

57111

Thank you for this referral. If the clinical or image interpretation does not parallel your findings or if I can be of any further assistance please contact me.

DATE

3-7-23

Nele Eley, DVM, Dr. med. vet., DipECVDI
European Specialist in Veterinary Diagnostic Imaging, Cert. Radiology,
Senior lecturer University of Giessen, Germany, Veterinary Faculty, Department of Radiology
Nele.Eley@sonopath.com