

**PATIENT PRESENTING CLINICAL SIGNS**

Gracie Saunders Chronic discharge from the nose, sneezing all the time.  
Abnormal PE/Chem/CBC/UA Results: Severe periodontal Dz

**SPECIES COMPUTED TOMOGRAPHIC STUDY OF THE HEAD**

Canine Plain and post contrast studies available for review.

**COMPUTED TOMOGRAPHIC FINDINGS****BREED**

The dentition is incomplete. Triadan 106 is absent.

Dachshund

Severe periodontal space widening with complete loss of the lamina dura of their dental alveolus is noted for the triadans 104, 105, and 204.

**SEX**

Spayed Female

Mild widening of the periodontium circumferential to the roots is present for the remainder of the premolar and molar teeth in all quadrants. Mild to moderate resorptive changes of the tooth roots are seen. Dental plaques are noted.

**AGE**

13 Years

Moderate turbinate destruction is seen in the ventral aspect of both nasal cavities with moderate regional swelling of the mucosal lining and mild fluid accumulation. The turbinates in the dorsal aspect of the nasal cavities are intact. The nasal septum and nasal bones are intact. The cribriform plate is intact.

The regional lymph nodes present within normal limits.

**INTERPRETED BY**

Nele Eley (Ondreka),  
DVM Dr. med. vet.,  
DipECVDI

**COMPUTED TOMOGRAPHIC DIAGNOSIS**

- Severe periodontal disease of the triadans 104, 105, 204 with dental-nasal fistula and moderate destructive rhinitis.

**INTERPRETATION OF FINDINGS & FURTHER RECOMMENDATIONS****HOSPITAL NAME**

Mobile Pet Imaging

The CT study reveals dental- nasal fistula formation secondary to severe chronic periodontal disease of the triadans 104, 105, 204. The destructive changes within the nasal cavities are likely a consequence of the chronic inflammatory/infection triggered by the dental disease and dental-nasal fistula formation. Dental revision and dental extractions with revision of the fistula recommended. Sampling for culture of both nasal cavities should be obtained.

**REFERRING VET**

Meaux

**INVOICE**

57112

**DATE**

3-7-23



**PATIENT**

Gracie Saunders

**SPECIES**

Canine

**BREED**

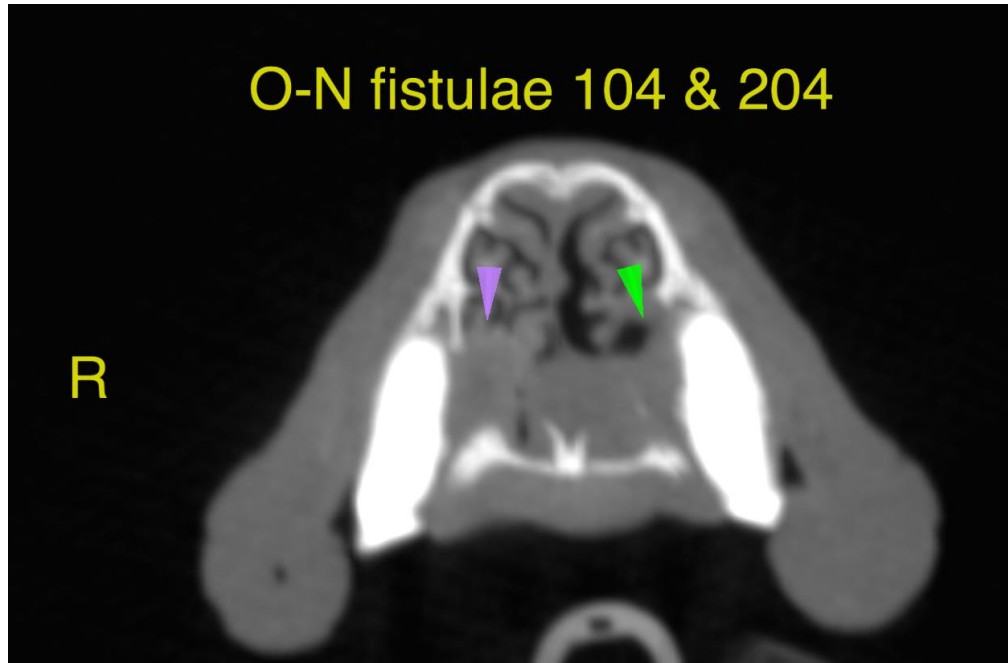
Dachshund

**SEX**

Spayed Female

**AGE**

13 Years



**INTERPRETED BY**

Nele Eley (Ondreka),  
DVM Dr. med. vet.,  
DipECVDI

The information and recommendations provided are based on the images presented by the referring veterinarian. No evaluation can be communicated regarding pathology that was not visible in the image/video clips provided.

Thank you for this referral. If the clinical or image interpretation does not parallel your findings or if I can be of any further assistance please contact me.

**HOSPITAL NAME**

Mobile Pet Imaging

**Nele Eley (Ondreka)**, DVM, Dr. med. vet., DipECVDI  
European Specialist in Veterinary Diagnostic Imaging, Cert. Radiology,  
Senior lecturer University of Giessen/Germany, Veterinary Faculty, Department of Radiology.  
Nele.Eley@sonopath.com

**REFERRING VET**

Meaux

**INVOICE**

57112

**DATE**

3-7-23