



**PATIENT**

Bella Macdonald

**PRESENTING CLINICAL SIGNS**

Chronic cough does well on steroids. Cough returns when dose tapers. Suspect bronchitis. Allergic?

**SPECIES**

Canine

**RADIOGRAPHIC STUDY OF THE THORAX**

Right/left lateral and ventrodorsal views of the thorax totaling 4 images available for review. Lateral view of the neck available for review.

**BREED**

Dalmation

Thoracic read requested.

**SEX**

FS

**RADIOGRAPHIC FINDINGS**

The degree of pulmonary inflation is fair. A moderate generalized bronchial lung pattern with marked peribronchial cuffing is noted. The peribronchial cuffing accentuates the caudodorsal lung field. Occasional age related incidental pulmonary osteomas are seen.

The cardiac silhouette presents within normal radiographic limits. No overall enlargement and no specific chamber enlargement is seen. The vertebral heart score is 10.

**AGE**

9

Course and width of the cervical and thoracic trachea present within normal limits.

The patient's body score appears to be excessive.

**INTERPRETED BY**

Nele Eley, DVM  
Dr. med. Vet. DipECVDI

**RADIOGRAPHIC DIAGNOSIS**

- Moderate generalized bronchial lung pattern with mild caudodorsal accentuation.

**INTERPRETATION OF THE FINDINGS & FURTHER RECOMMENDATIONS**

The radiographic findings are compatible with active lower airway disease. Differential diagnosis includes eosinophilic / allergic bronchopneumopathy as well as infectious bronchitis including viral, bacterial, and parasitic. The patient's history in combination with the radiographic findings renders allergic bronchopneumopathy more likely than infectious bronchitis even though this cannot be ruled out entirely.

**HOSPITAL NAME**

Sunridge Veterinary  
Clinic

**REFERRING VET**

Dr. Duncan

**INVOICE**

57116

**DATE**

3-7-23



**PATIENT**

Bella Macdonald

**SPECIES**

Canine

**BREED**

Dalmation

**SEX**

FS

**AGE**

9

**INTERPRETED BY**

Nele Eley, DVM  
Dr. med. Vet. DipECVDI

**HOSPITAL NAME**

Sunridge Veterinary  
Clinic

**REFERRING VET**

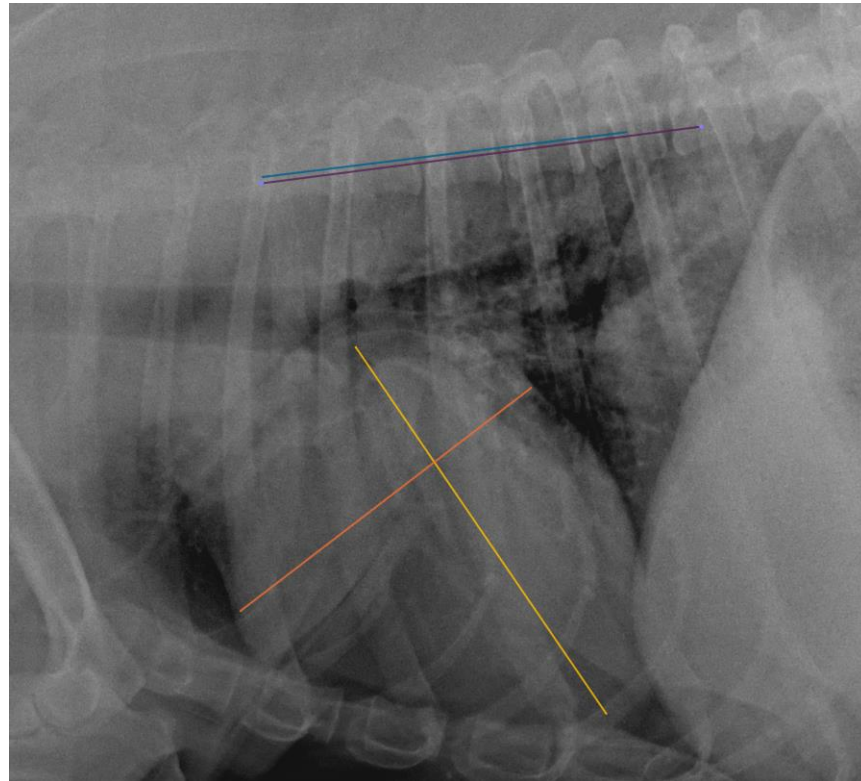
Dr. Duncan

**INVOICE**

57116

**DATE**

3-7-23



The information and recommendations provided are based on the images presented by the referring veterinarian/sonographer. No evaluation can be communicated regarding pathology that was not visible in the image/video clips provided.

Thank you for this referral. If the clinical or image interpretation does not parallel your findings or if I can be of any further assistance please contact me.

**Nele Eley**, DVM, Dr. med. vet., DipECVDI  
European Specialist in Veterinary Diagnostic Imaging, Cert. Radiology,  
Senior lecturer University of Giessen, Germany, Veterinary Faculty, Department of Radiology  
Nele.Eley@sonopath.com