SonoPath Teleradiology

EDUCATIONAL TELECONSULTATION SERVICES™

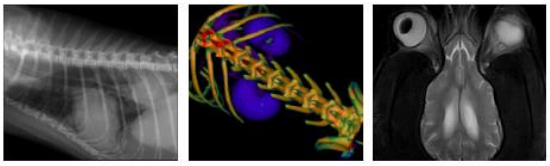

SonoPath.com
1-800-838-4268 info@sonopath.com

PATIENT

Oscar Burns

SPECIES

Feline

BREED

Domestic Shorthair

SEX

Male Neutered

AGE

13 Years

INTERPRETED BY

Nele Eley, DVM
Dr. med. Vet. DipECVDI

HOSPITAL NAME

New Bridge
Veterinary Practice

REFERRING VET

Dr. Abina Glennon

INVOICE

50779

DATE

3-7-22

PRESENTING CLINICAL SIGNS

Howling at night
Abnormal PE/Chem/CBC/UA Results: CBC/CHEM/T4/UA WNL

RADIOGRAPHIC STUDY OF THE ABDOMEN

Right lateral and ventrodorsal views totaling 2 images available for review.

RADIOGRAPHIC FINDINGS

A large round soft tissue opacity is seen in the caudal abdomen adjacent to the ventral abdominal wall and presumed to represent the urinary bladder.

A second ovoid well delineated soft tissue opaque structure of 4.8 cm length and 3.0 cm diameter is seen caudal and to the left of the urinary bladder.

An additional ovoid soft tissue opaque mass effect is seen dorsally within the caudal sublumbar area and can be traced into the dorsal aspect of the pelvic inlet.

The kidneys are not directly seen in their usual position in both the lateral and orthogonal views.

The patient has 6 lumbar vertebrae.

Early spondylosis deformans is seen in the mid lumbar spine.

Mild lumbosacral spondylosis deformans is seen.

There is a transitional lumbosacral and sacrocaudal vertebra.

RADIOGRAPHIC DIAGNOSIS

- Caudal abdominal and pelvic soft tissue mass effects of undetermined origin.
- Distended urinary bladder.

INTERPRETATION OF THE FINDINGS & FURTHER RECOMMENDATIONS

The ovoid mass of 4.8 cm length caudal and to the left of the urinary bladder may theoretically represent the ectopic left kidney. Renal origin of the 2nd partially intrapelvic soft tissue mass; however, is thought unlikely and differential diagnosis includes sublumbar lymphadenomegaly and other soft tissue mass. Ultrasound is required in this patient for further definition.

SonoPath Teleradiology

EDUCATIONAL TELECONSULTATION SERVICES™

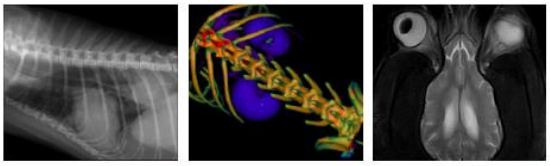

SonoPath.com
1-800-838-4268 info@sonopath.com

PATIENT

Oscar Burns

SPECIES

Feline

BREED

Domestic Shorthair

SEX

Male Neutered

AGE

13 Years

INTERPRETED BY

Nele Eley, DVM
Dr. med. Vet. DipECVDI

HOSPITAL NAME

New Bridge
Veterinary Practice

REFERRING VET

Dr. Abina Glennon

INVOICE

50779

DATE

3-7-22

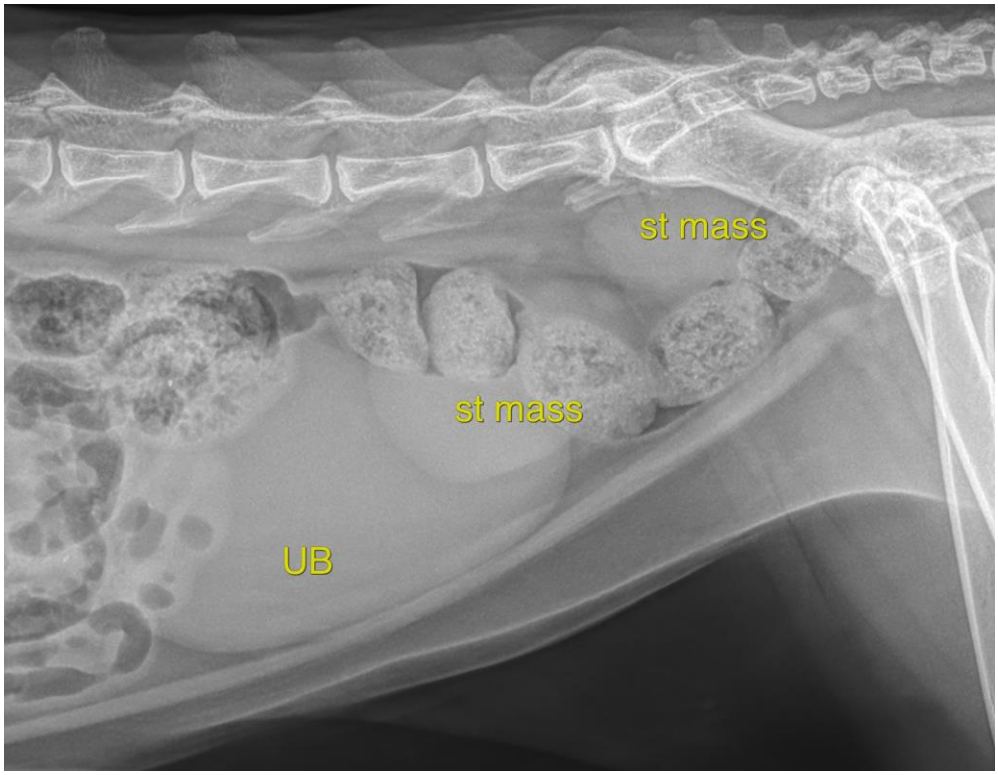

The information and recommendations provided are based on the images presented by the referring veterinarian/sonographer. No evaluation can be communicated regarding pathology that was not visible in the image/video clips provided.

Thank you for this referral. If the clinical or image interpretation does not parallel your findings or if I can be of any further assistance please contact me.

Nele Eley, DVM, Dr. med. vet., DipECVDI
European Specialist in Veterinary Diagnostic Imaging, Cert. Radiology,
Senior lecturer University of Giessen, Germany, Veterinary Faculty, Department of Radiology
Nele.Eley@sonopath.com