

**PATIENT**

Leeloo Cropper

PRESENTING CLINICAL SIGNS

Has been panting a lot and coughing. The coughing happens when laying down most of the time. This all have been going on since April of 2020.
Abnormal PE/Chem/CBC/UA Results: PE: SCLEROSIS NORMAL FOR AGE WORN TEETH.
NO RECENT BLOOD WORK

SPECIES

Canine

RADIOGRAPHIC STUDY OF THE THORAX & NECK

Right and left lateral views of the thorax and lateral and ventrodorsal views of the neck totaling 5 images available for review.

BREEDCatahoula Leopard
Dog Mix**RADIOGRAPHIC FINDINGS****Thorax**

Mild to moderate spondyloses are present within the caudal thoracic spine.

SEX

Spayed

The degree of pulmonary inflation is fair. A mild generalized bronchointerstitial lung pattern is seen.

Mild redundancy of the dorsal tracheal ligament is noted cranial of the thoracic inlet.

AGE

12 Years, 5 Months

There is no evidence of mediastinal widening or lymphadenomegaly.

The vertebral heart score is 10.5. The radiographic presentation of the cardiac silhouette is within normal limits.

INTERPRETED BYNele Eley, DVM
Dr. med. Vet. DipECVDI**Neck**

The radiographic presentation of the hyoid bone, larynx, and cervical trachea is within normal limits.

HOSPITAL NAMEElizabeth Animal
Hospital

Mild upper esophageal aerophagia is seen and considered incidental.

RADIOGRAPHIC DIAGNOSIS

- Mild generalized bronchial lung pattern.
- Normal radiographic presentation of the trachea and cardiovascular system.

REFERRING VET

Leon Anderson, DVM

INTERPRETATION OF THE FINDINGS & FURTHER RECOMMENDATIONS

A mild generalized bronchial lung pattern is noted which may well be within age related normal limits. Low grade lower airway disease such as eosinophilic bronchopneumopathy or infectious bronchitis cannot be ruled out entirely.

INVOICE

50780

The radiographic presentation of the cardiovascular system and trachea was within normal limits. Upper airway pathology such as laryngeal malfunction or other cannot be ruled out based on radiographs.

DATE

3-7-22

Upper and lower airway endoscopy could be considered for further definition if indicated per the clinical signs.



PATIENT

Leeloo Cropper

SPECIES

Canine

BREED

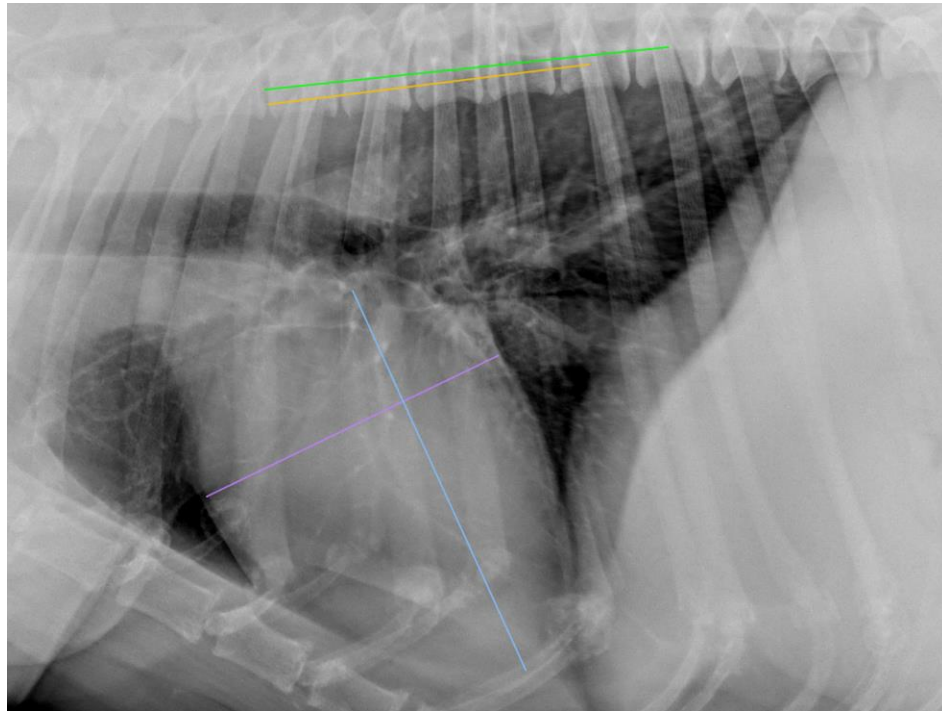
Catahoula Leopard
Dog Mix

SEX

Spayed

AGE

12 Years, 5 Months



INTERPRETED BY

Nele Eley, DVM
Dr. med. Vet. DipECVDI

The information and recommendations provided are based on the images presented by the referring veterinarian/sonographer. No evaluation can be communicated regarding pathology that was not visible in the image/video clips provided.

Thank you for this referral. If the clinical or image interpretation does not parallel your findings or if I can be of any further assistance please contact me.

HOSPITAL NAME

Elizabeth Animal
Hospital

Nele Eley, DVM, Dr. med. vet., DipECVDI
European Specialist in Veterinary Diagnostic Imaging, Cert. Radiology,
Senior lecturer University of Giessen, Germany, Veterinary Faculty, Department of Radiology
Nele.Eley@sonopath.com

REFERRING VET

Leon Anderson, DVM

INVOICE

50780

DATE

3-7-22