

**PATIENT**

Mudge Lytle

**PRESENTING CLINICAL SIGNS**

Chronic dry, hacking, non-productive cough noted at home. New Grade IV heart murmur ausculted during examination.

**SPECIES**

Canine

**RADIOGRAPHIC STUDY OF THE THORAX**

Right/left lateral and dorsoventral views totaling 3 images available for review.

**BREED**

Jack Russel Terrier

**RADIOGRAPHIC FINDINGS**

The patient's body score is excessive.

**SEX**

FS

Moderate left sided cardiomegaly is noted with a vertebral heart score of 12, left atrial tenting, and a double opacity sign. Bronchial splitting and elevation of the trachea are noted. The pulmonary veins are mildly dilated. No evidence of pulmonary edema is seen at this time.

The lung presents a mild generalized bronchial pattern.

Mild gastric aerophagia is noted.

**AGE**

10 Years, 9 Months

**RADIOGRAPHIC DIAGNOSIS**

- Moderate left sided cardiomegaly with suspect emerging congestive cardiac failure.
- Otherwise, normal age related lung.

**INTERPRETED BY**

Nele Eley, DVM  
Dr. med. Vet. DipECVDI

**INTERPRETATION OF THE FINDINGS & FURTHER RECOMMENDATIONS**

The radiographic study reveals moderate left sided cardiomegaly with pulmonary venous congestion suggesting ongoing cardiac failure. Cardiogenic pulmonary edema is not evident (yet). Myxomatous degeneration of the mitral valve with mitral valve regurgitation is considered most likely as underlying cause. However, a full cardiac echo is required for further definition and to adjust the medical treatment accordingly.

**HOSPITAL NAME**

Gentle Doctor Animal  
Hospital

The mass effect of the enlarged left atrium on the left main lobar bronchus may be the cause of the coughing.

**REFERRING VET**

Dr. Sergio Valadez

**INVOICE**

57086

**DATE**

3-6-23



**PATIENT**

Mudge Lytle

**SPECIES**

Canine

**BREED**

Jack Russel Terrier

**SEX**

FS

**AGE**

10 Years, 9 Months

**INTERPRETED BY**

Nele Eley, DVM  
Dr. med. Vet. DipECVDI

**HOSPITAL NAME**

Gentle Doctor Animal  
Hospital

**REFERRING VET**

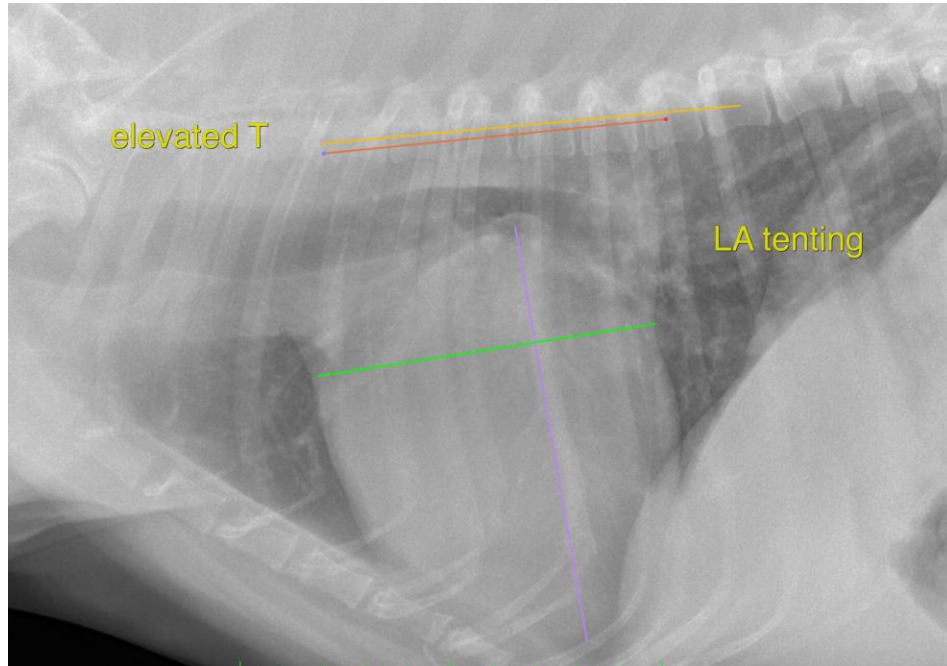
Dr. Sergio Valadez

**INVOICE**

57086

**DATE**

3-6-23



The information and recommendations provided are based on the images presented by the referring veterinarian/sonographer. No evaluation can be communicated regarding pathology that was not visible in the image/video clips provided.

Thank you for this referral. If the clinical or image interpretation does not parallel your findings or if I can be of any further assistance please contact me.

**Nele Eley**, DVM, Dr. med. vet., DipECVDI  
European Specialist in Veterinary Diagnostic Imaging, Cert. Radiology,  
Senior lecturer University of Giessen, Germany, Veterinary Faculty, Department of Radiology  
Nele.Eley@sonopath.com