



PATIENT PRESENTING CLINICAL SIGNS

Ella Ciltea 1 yr old maltese , started being ataxic 2 days before presentation . Yelped and became acutely non-ambulatory a day before presentation. Continued to show neck pain since then. No history of trauma reported.

SPECIES Abnormal PE/Chem/CBC/UA Results: Cranial nerves: abnormal - weak menace OU
Canine Proprioception: abnormal - delayed CP in left thoracic and pelvic limb, very mildly delayed in right thoracic and pelvic limb Gait: weakly ambulatory, falls to the left, pelvic limb paresis and ataxia Spinal reflexes: weak withdrawl in all limbs Spinal palpation: did not manipulate neck too much but is very guarded and reduced ROM, no back pain Very mild left sided head tilt and keeps head turned to the left CBC, Biochem - normal

BREED Maltese

COMPUTED TOMOGRAPHIC STUDY OF THE CERVICAL SPINE

Plain and post contrast studies in soft tissue and bone windows available for review.

SEX COMPUTED TOMOGRAPHIC FINDINGS

SF The odontoid peg is blunted and short.

AGE Severe caudodorsal atlantoaxial subluxation and axis rotation are seen. The vertebral canal height is reduced by more than 50% of its original diameter. Severe upper cervical spinal cord compression can be assumed. The dorsal and ventral atlas arches are fully developed and closed. The dorsal arch of the atlas is in a relative cranial position and appears to have potential to cause cerebellar impingement. The supraoccipital bone is short and steep. The foramen magnum is enlarged. The basioccipital bone is short. No evidence of fracture or separated ossification centers of the axis is seen.

1 Year

INTERPRETED BY

Nele Eley, DVM
 Dr. med. Vet. DipECVDI

Moderate bilateral lateral ventricle enlargement mild supraoccipital fluid accumulation are noted.

HOSPITAL NAME COMPUTED TOMOGRAPHIC DIAGNOSIS

Animal Health Partners

- Severe atlantoaxial subluxation and brachycephalic conformation of the craniocervical junction.

REFERRING VET INTERPRETATION OF THE FINDINGS & FURTHER RECOMMENDATIONS

Dr. Marchal

The CT study reveals a typical brachycephalic craniocervical junction conformation with severe atlantoaxial subluxation. The causes are typically complex, and underdevelopment of the odontoid peg may contribute as well as weakness of the atlantoaxial and occipital ligaments and membranes. In this patient, the degree of vertebral canal stenosis and spinal cord compression appears severe. No evidence of traumatic injury is seen.

INVOICE

50752

DATE

3-6-22



PATIENT

Ella Ciltea

SPECIES

Canine

BREED

Maltese

SEX

SF

AGE

1 Year

INTERPRETED BY

Nele Eley, DVM
Dr. med. Vet. DipECVDI

HOSPITAL NAME

Animal Health
Partners

REFERRING VET

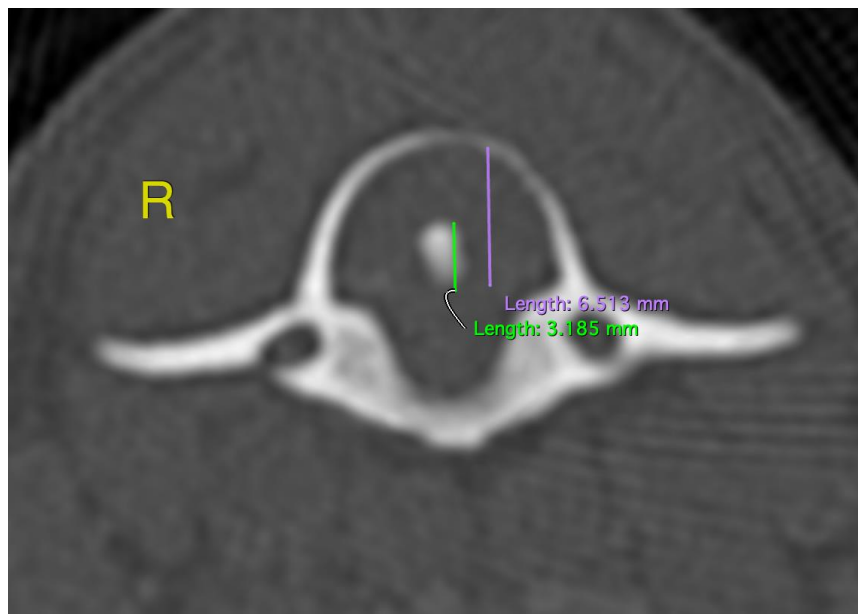
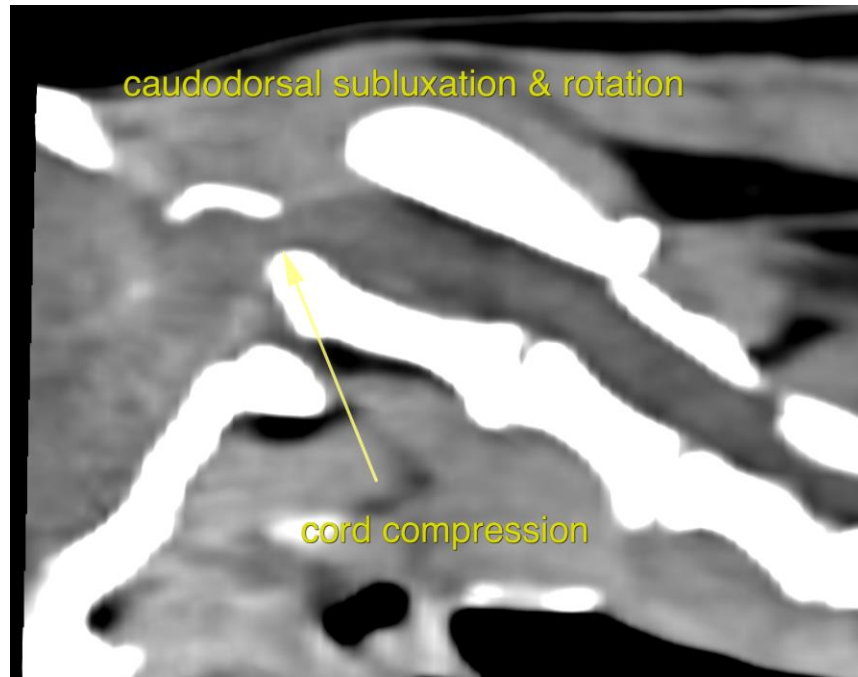
Dr. Marchal

INVOICE

50752

DATE

3-6-22





PATIENT

Ella Ciltea

The information and recommendations provided are based on the images presented by the referring veterinarian/sonographer. No evaluation can be communicated regarding pathology that was not visible in the image/video clips provided.

Thank you for this referral. If the clinical or image interpretation does not parallel your findings or if I can be of any further assistance please contact me.

SPECIES

Canine

Nele Eley, DVM, Dr. med. vet., DipECVDI
European Specialist in Veterinary Diagnostic Imaging, Cert. Radiology,
Senior lecturer University of Giessen, Germany, Veterinary Faculty, Department of Radiology
Nele.Eley@sonopath.com

BREED

Maltese

SEX

SF

AGE

1 Year

INTERPRETED BY

Nele Eley, DVM
Dr. med. Vet. DipECVDI

HOSPITAL NAME

Animal Health
Partners

REFERRING VET

Dr. Marchal

INVOICE

50752

DATE

3-6-22