



PATIENT

Emma Ray

SPECIES

Canine

BREED

Saint Bernard Mix

SEX

F

AGE

9 Months

INTERPRETED BY

Nele Eley, DVM
Dr. med. Vet. DipECVDI

HOSPITAL NAME

Southern Oregon
Veterinary Specialty
Center

REFERRING VET

Rory Applegate

INVOICE

57067

DATE

3-5-23

PRESENTING CLINICAL SIGNS

2 month history trauma on the nasal planum. Purulent discharge at bite site with incomplete response to antibiotic support. Probing of the area showed disruption of the nose and communication with the left nasal passage. CT and probing of the area with biopsy and culture performed.

COMPUTED TOMOGRAPHIC STUDY OF THE HEAD

Plain and post contrast studies available for review.

COMPUTED TOMOGRAPHIC FINDINGS

The patient has a history of bite injury to the nose.

A hypodense ill-defined tract can be seen within the dorsal and lateral aspect of the left nasal bone entering the left nasal cavity approximately 6 cm caudal to the left nostril. Reduced and heterogeneous bone density is noted throughout the drainage tract with moderate generalized osseous thickening. Mild regional turbinate destruction and mucosal swelling are noted in the left nasal cavity.

There is moderate regional soft tissue swelling with irregular shaped 2mm sized bone pieces dorsal to the osseous tract.

COMPUTED TOMOGRAPHIC DIAGNOSIS

- Regional osteitis with drainage tract in the left nasal bone with nasal fistula and mild regional destructive rhinitis.
- Suspect small sequestrum in the osseous drainage tract and in the soft tissues dorsal to the drainage tract.

INTERPRETATION OF THE FINDINGS & FURTHER RECOMMENDATIONS

The CT findings are compatible with nasal fistula after bite injury with regional osteitis and drainage tract formation. Regional osteonecrosis with sequestration of the affected bone and a small sequestrum in the soft tissues dorsal to the drainage tract are suspected as well.



PATIENT

Emma Ray

SPECIES

Canine

BREED

Saint Bernard Mix

SEX

F

AGE

9 Months

INTERPRETED BY

Nele Eley, DVM
Dr. med. Vet. DipECVDI

HOSPITAL NAME

Southern Oregon
Veterinary Specialty
Center

REFERRING VET

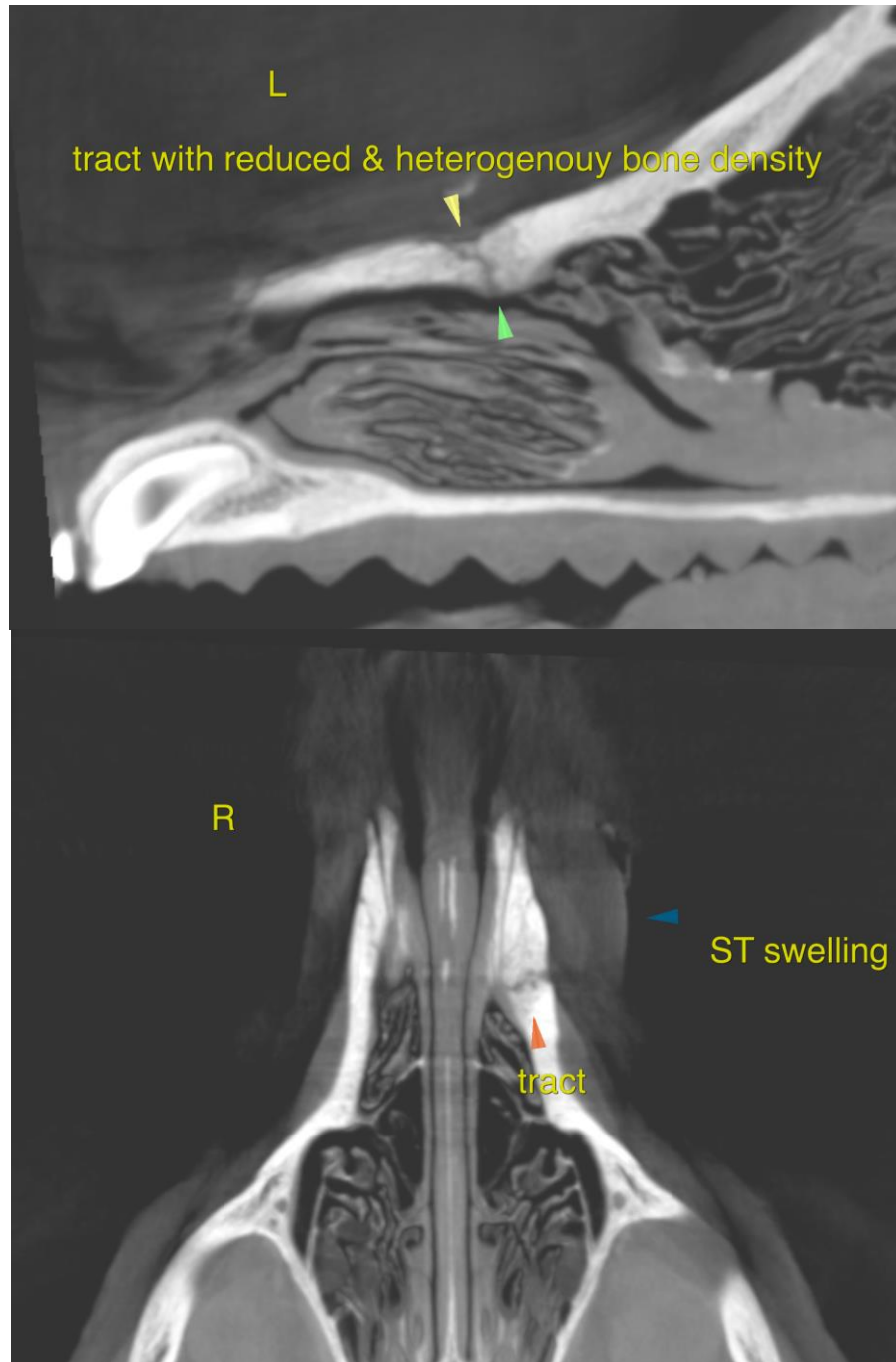
Rory Applegate

INVOICE

57067

DATE

3-5-23





PATIENT

Emma Ray

The information and recommendations provided are based on the images presented by the referring veterinarian/sonographer. No evaluation can be communicated regarding pathology that was not visible in the image/video clips provided.

SPECIES

Canine

Thank you for this referral. If the clinical or image interpretation does not parallel your findings or if I can be of any further assistance please contact me.

BREED

Saint Bernard Mix

Nele Eley, DVM, Dr. med. vet., DipECVDI
European Specialist in Veterinary Diagnostic Imaging, Cert. Radiology,
Senior lecturer University of Giessen, Germany, Veterinary Faculty, Department of Radiology
Nele.Eley@sonopath.com

SEX

F

AGE

9 Months

INTERPRETED BY

Nele Eley, DVM
Dr. med. Vet. DipECVDI

HOSPITAL NAME

Southern Oregon
Veterinary Specialty
Center

REFERRING VET

Rory Applegate

INVOICE

57067

DATE

3-5-23