



PATIENT PRESENTING CLINICAL SIGNS

Ripley Barden She is having a hard time getting up out of a sitting position. She did not want to get out of bed this AM. She was having a hard time getting her right leg up over the step. Whined once this morning. She does not seem in pain when poking around. She as a hard time getting down to sit. In the room she did not put any weight on her R hind leg when getting up from laying down.
SPECIES Abnormal PE/Chem/CBC/UA Results: LIMPING RIGHT HIND BUTTRESS RIGHT STIFLE UNCOMFORTABLE IN BOTH REAR
 Canine

RADIOGRAPHIC STUDY OF THE PELVIS & STIFLES

BREED Mediolateral and craniocaudal views of both stifles and ventrodorsal hip extended and lateral views of the pelvis totaling 7 images available for review.
 Rott

RADIOGRAPHIC FINDINGS

SEX Pelvis

FS The pelvic bones and coxofemoral joints present within age related normal limits. No signs of hip dysplasia are seen.

AGE The muscle volume of both hind limbs is adequate and symmetric.

7 Months, 1 Week **Stifles**

INTERPRETED BY The radiographic examination of the stifles reveals bilateral articular swelling of the stifle joints. The articular swelling is moderate to severe on the right and moderate on the left side.

Nele Eley, DVM
 Dr. med. Vet. DipECVDI

No evidence of cranial thrust of the tibia is seen. There are no subchondral bone defects. There is no evidence of soft tissue swelling level with the digital extensor origin and growth plate closure is within normal limits.

HOSPITAL NAME

EI

RADIOGRAPHIC DIAGNOSIS

- Bilateral stifle arthropathy with articular swelling.

REFERRING VET

Kim Allyn, DVM

INTERPRETATION OF THE FINDINGS & FURTHER RECOMMENDATIONS

The articular swelling is bilateral even though more pronounced on the right side. The radiographic swelling may represent synovial thickening and effusion or a combination of these. No specific signs of cruciate ligament or other articular injury are seen and the immune mediated and other arthritis should be included in the diagnostic algorithm of this patient owing to the bilateral appearance.

INVOICE

50759

DATE

3-5-22



PATIENT

Ripley Barden

SPECIES

Canine

BREED

Rott

SEX

FS

AGE

7 Months, 1 Week

INTERPRETED BY

Nele Eley, DVM
Dr. med. Vet. DipECVDI

HOSPITAL NAME

EI

REFERRING VET

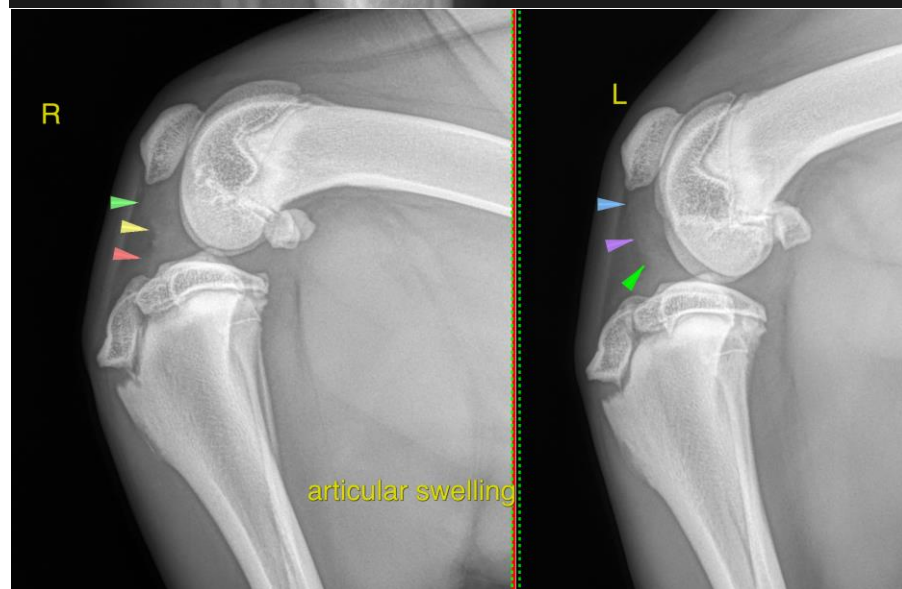
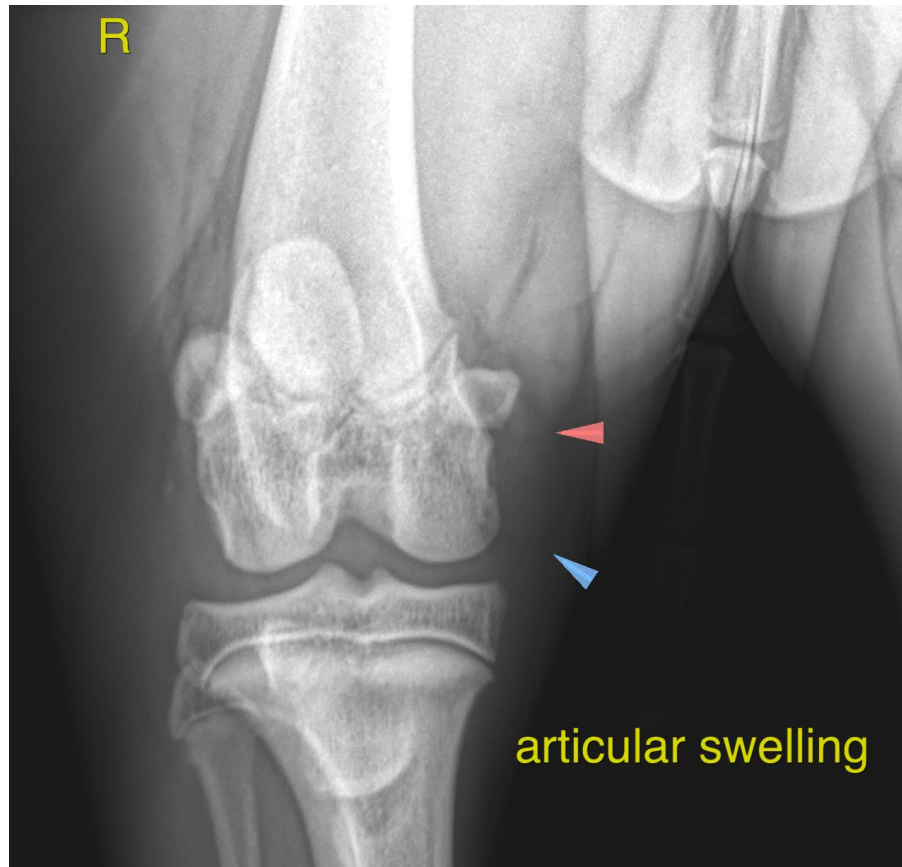
Kim Allyn, DVM

INVOICE

50759

DATE

3-5-22





PATIENT

Ripley Barden

The information and recommendations provided are based on the images presented by the referring veterinarian/sonographer. No evaluation can be communicated regarding pathology that was not visible in the image/video clips provided.

Thank you for this referral. If the clinical or image interpretation does not parallel your findings or if I can be of any further assistance please contact me.

SPECIES

Canine

Nele Eley, DVM, Dr. med. vet., DipECVDI
European Specialist in Veterinary Diagnostic Imaging, Cert. Radiology,
Senior lecturer University of Giessen, Germany, Veterinary Faculty, Department of Radiology
Nele.Eley@sonopath.com

BREED

Rott

SEX

FS

AGE

7 Months, 1 Week

INTERPRETED BY

Nele Eley, DVM
Dr. med. Vet. DipECVDI

HOSPITAL NAME

EI

REFERRING VET

Kim Allyn, DVM

INVOICE

50759

DATE

3-5-22