



PATIENT PRESENTING CLINICAL SIGNS

Pearl Tomassi Throwing up last three days once per day vomited at different times vomited 3hrs after eating this morning 5% dehydration

SPECIES RADIOGRAPHIC STUDY OF THE ABDOMEN

Canine Right/left lateral and ventrodorsal views totaling 4 images available for review.

RADIOGRAPHIC FINDINGS

BREED The surrounding bony structures are within normal limits.
Shih Poo X

No abnormalities of the extraabdominal soft tissues are noted. The abdominal wall is smooth and thin.

SEX The serosal detail is maintained throughout the peritoneal and retroperitoneal space.

Female Spayed The liver is appropriate in position, size and presents uniform opacity.

AGE The splenic head is in the anticipated position and within normal limits for size and opacity. The splenic body and tail are considered normal for position, size, shape and opacity.

11 Months Both kidneys are seen and present with normal size, shape, delineation and opacity. The urinary bladder is in its anticipated position. No radiopaque calculi are noted throughout the upper and lower urinary tract.

INTERPRETED BY

Nele Eley, DVM
Dr. med. Vet. DipECVDI

The stomach contains a mild amount of gas. A relatively rigid gas column is seen within the gastric outlet and descending duodenum on all available images.

HOSPITAL NAME

Truscott Animal
Hospital

No evidence of abnormal small intestinal dilation, radiopaque foreign material, or plication is noted.

The cecum and colon present within the expected limits.

RADIOGRAPHIC DIAGNOSIS

- Gastroduodenal maldigestion pattern.

REFERRING VET

Mina Abdelsayed

INTERPRETATION OF THE FINDINGS & FURTHER RECOMMENDATIONS

INVOICE

50761

The radiographic study reveals no signs of mechanical ileus. A gastroduodenal maldigestion pattern is noted which may be a consequence of altered motility, inflammation, infection, or metabolic disease. Subileus can never be ruled out entirely. Consider obtaining recheck radiographs or performing abdominal ultrasound in case of persisting or deteriorating clinical signs.

DATE

3-5-22



PATIENT

Pearl Tomassi

SPECIES

Canine

BREED

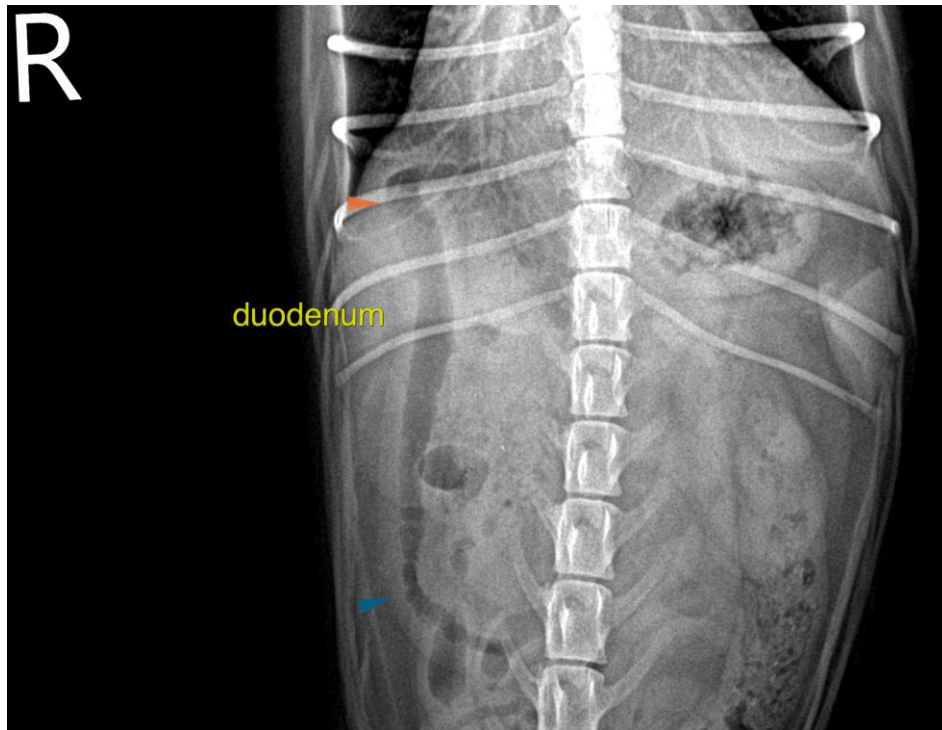
Shih Poo X

SEX

Female Spayed

AGE

11 Months



INTERPRETED BY

Nele Eley, DVM
Dr. med. Vet. DipECVDI

The information and recommendations provided are based on the images presented by the referring veterinarian/sonographer. No evaluation can be communicated regarding pathology that was not visible in the image/video clips provided.

HOSPITAL NAME

Truscott Animal
Hospital

Thank you for this referral. If the clinical or image interpretation does not parallel your findings or if I can be of any further assistance please contact me.

Nele Eley, DVM, Dr. med. vet., DipECVDI
European Specialist in Veterinary Diagnostic Imaging, Cert. Radiology,
Senior lecturer University of Giessen, Germany, Veterinary Faculty, Department of Radiology
Nele.Eley@sonopath.com

REFERRING VET

Mina Abdelsayed

INVOICE

50761

DATE

3-5-22