



PATIENT

Mickey Harding

PRESENTING CLINICAL SIGNS

Several month hx of productive cough. Owner states he sounds congested and often has terminal retch.

Abnormal PE/Chem/CBC/UA Results: Cardiothoracic auscultation is unremarkable. No murmur noted. SPO2 92%, HR 130, panting. Temp 101.1F. BW not performed today

SPECIES

Canine

RADIOGRAPHIC STUDY OF THE THORAX

Right/left lateral and ventrodorsal views of the thorax totaling 3 images available for review.

BREED

Yorkshire Terrier

RADIOGRAPHIC FINDINGS

The degree of pulmonary inflation is moderate. A moderate generalized bronchointerstitial lung pattern with mild peribronchial cuffing is noted.

SEX

Mild caudocervical tracheal collapse and redundancy of the tracheal membrane are seen.

MN

The cardiac silhouette presents within normal limits. The vertebral heart score is 9.9.

AGE

13 Years

Multiple spondyloses are noted within the caudal cervical, caudal thoracic, and cranial lumbar spine.

RADIOGRAPHIC DIAGNOSIS

- Suspect dynamic tracheal disease.
- Generalized bronchointerstitial lung pattern.

INTERPRETED BY

Nele Eley, DVM
Dr. med. Vet. DipECVDI

INTERPRETATION OF THE FINDINGS & FURTHER RECOMMENDATIONS

The radiographic study reveals a moderate generalized bronchointerstitial lung pattern. Differential diagnosis includes eosinophilic / allergic bronchopneumopathy and infectious bronchitis such as viral, bacterial, and parasitic.

HOSPITAL NAME

Ruidoso Animal Clinic

There also is evidence of dynamic tracheal disease even though the degree of collapse of the caudocervical trachea is mild, at least during the radiographic examination. Clinical correlation is required.

REFERRING VET

Sarah Botkin

Consider a clinical trial of treatment for bronchitis with lung worm testing versus further definition by means of upper and lower airway endoscopy with airway sampling.

INVOICE

57064

DATE

3-4-23



PATIENT

Mickey Harding

SPECIES

Canine

BREED

Yorkshire Terrier

SEX

MN

AGE

13 Years

INTERPRETED BY

Nele Eley, DVM
Dr. med. Vet. DipECVDI

HOSPITAL NAME

Ruidoso Animal Clinic

REFERRING VET

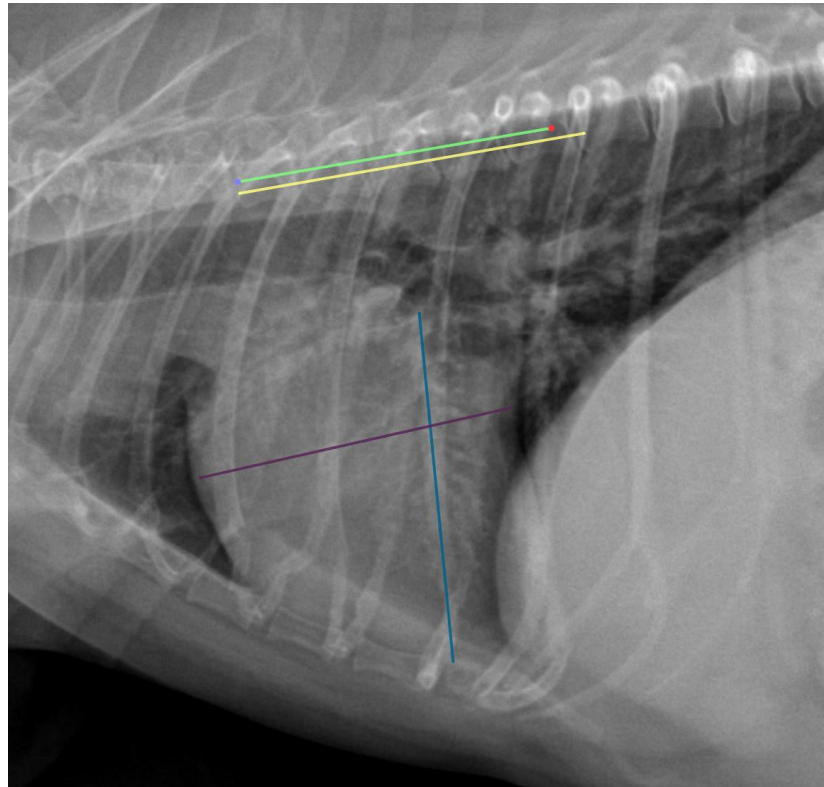
Sarah Botkin

INVOICE

57064

DATE

3-4-23



The information and recommendations provided are based on the images presented by the referring veterinarian/sonographer. No evaluation can be communicated regarding pathology that was not visible in the image/video clips provided.

Thank you for this referral. If the clinical or image interpretation does not parallel your findings or if I can be of any further assistance please contact me.

Nele Eley, DVM, Dr. med. vet., DipECVDI
European Specialist in Veterinary Diagnostic Imaging, Cert. Radiology,
Senior lecturer University of Giessen, Germany, Veterinary Faculty, Department of Radiology
Nele.Eley@sonopath.com