



PATIENT

Jaxx Musgrave

SPECIES

Canine

BREED

Labrador Mix

SEX

Neutered Male

AGE

8Y

WEIGHT

43.1kg

INTERPRETED BY

Nele Eley (Ondreka),
DVM Dr. med. vet.,
DipECVDI

IMAGING PERFORMED BY

Dr. David Lane

HOSPITAL NAME

Points East West
Veterinary Services

REFERRING VET

Natalie Yoguel and David
Lane

INVOICE

74423

DATE

3-31-26

PRESENTING CLINICAL SIGNS

Grade 2/5 weight bearing left forelimb lameness at a trot of several weeks duration, after running in the snow. Waxing and waning and exacerbated by activity. Improves some with Metacam. On exam pain with hyperflexion of the left shoulder and extension with reduced ROM. Pain on flexors of medial elbows bilateral with reduced ROM in flexion. Radiographs taken today confirm OA of the left shoulder.

ULTRASONOGRAPHIC FINDINGS

Left Shoulder

Average maximum thickness of the left supraspinatus tendon is 9mm. The supraspinatus tendon appears to be diffusely thickened with mild structural remodeling and mild biceps impingement.

Moderate to severe effusion with marked synovial thickening and synovial proliferations of the left biceps tendon sheath is seen. Moderate exostosis formation with irregular surface is seen in the bicipital groove. The biceps tendon structure remains intact.

Moderate joint effusion appears to be present with mild periarticular osseous remodeling.

Mild enthesiopathy at the subscapularis tendon insertion is seen.

Right Shoulder

Average maximum thickness of the right supraspinatus tendon is 9mm. The supraspinatus tendon appears to be diffusely thickened with mild structural remodeling and mild biceps impingement.

Mild synovial thickening and mild effusion of the biceps tendon sheath are present. There is mild exostosis formation within the bicipital groove. The biceps tendon tissue is structurally normal.

Visible parts of the subscapularis tendon are unremarkable.

ULTRASONOGRAPHIC DIAGNOSIS

- Moderate to severe left sided chronic bicipital tenosynovitis with biceps impingement.
- Mild chronic left supraspinatus tendinopathy.
- Presumed chronic degenerative joint disease/osteoarthritis of the left shoulder.
- Mild right sided supraspinatus tendinopathy.
- Mild right sided chronic biceps tenosynovitis.

INTERPRETATION OF FINDINGS & FURTHER RECOMMENDATIONS

The left shoulder findings are consistent with chronic significant bicipital tenosynovitis likely representing a source of lameness. Mild mechanical impingement of the biceps tendon secondary to supraspinatus tendinopathy is likely contributing to the clinical signs as well.

The right sided changes are mild and may be subclinical.

Conservative management using NSAIDS, controlled activity, physiotherapy, and biologic treatment may be attempted. Arthroscopic evaluation and surgical management can be considered should conservative management fail.



PATIENT

Jaxx Musgrave

SPECIES

Canine

BREED

Labrador Mix

SEX

Neutered Male

AGE

8Y

WEIGHT

43.1kg

INTERPRETED BY

Nele Eley (Ondreka),
DVM Dr. med. vet.,
DipECVDI

IMAGING PERFORMED BY

Dr. David Lane

HOSPITAL NAME

Points East West
Veterinary Services

REFERRING VET

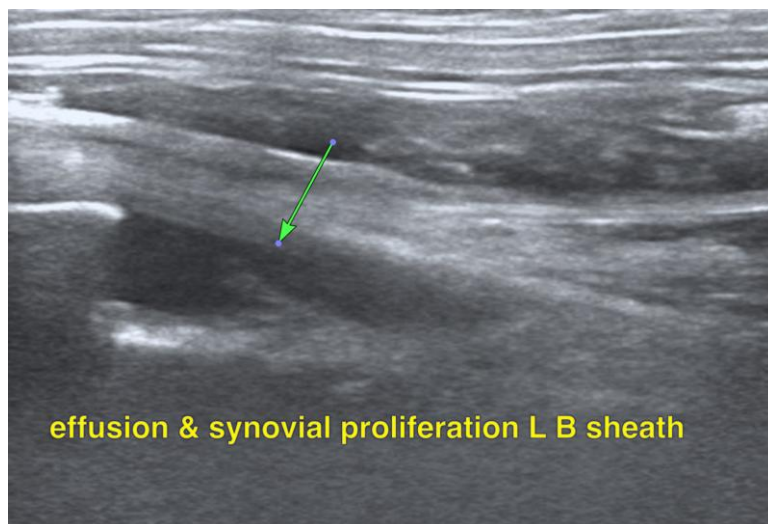
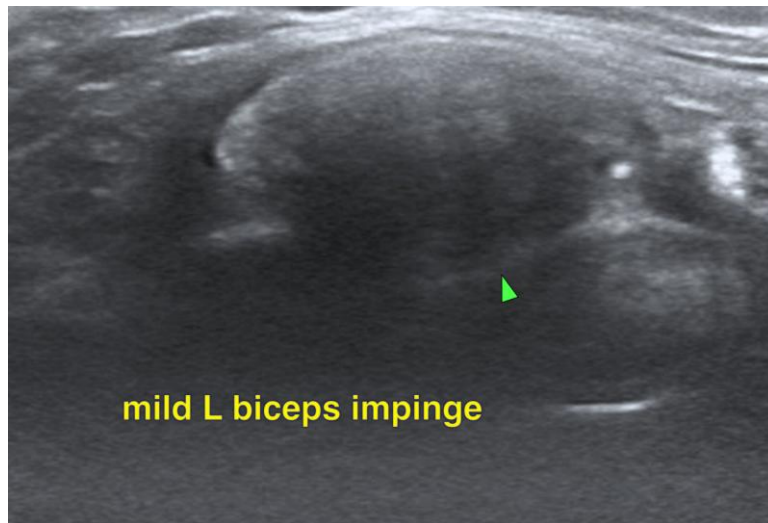
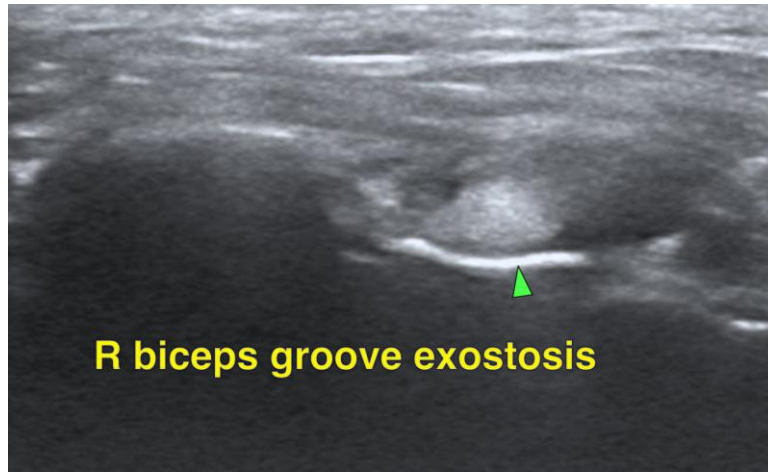Natalie Yoguel and David
Lane

INVOICE

74423

DATE

3-31-26





PATIENT

Jaxx Musgrave

SPECIES

Canine

BREED

Labrador Mix

SEX

Neutered Male

AGE

8Y

WEIGHT

43.1kg

INTERPRETED BY

Nele Eley (Ondreka),
DVM Dr. med. vet.,
DipECVDI

IMAGING PERFORMED BY

Dr. David Lane

HOSPITAL NAME

Points East West
Veterinary Services

REFERRING VET

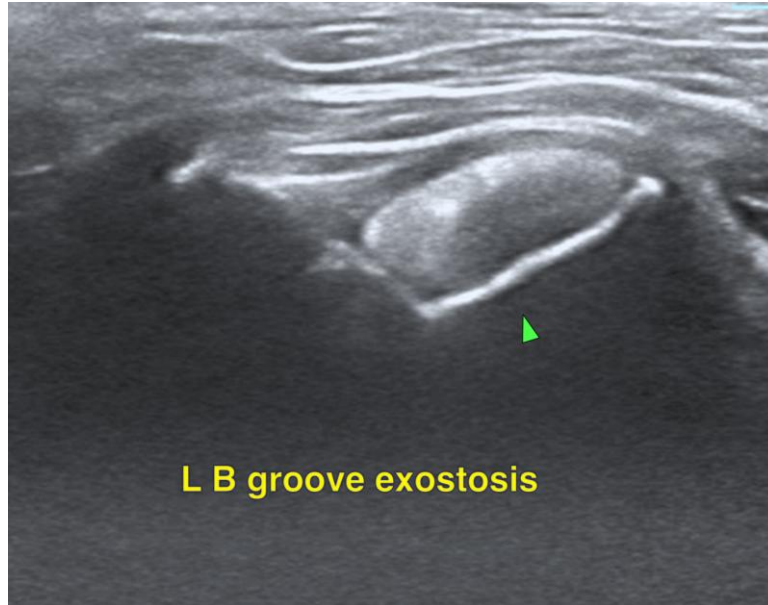
Natalie Yoguel and David
Lane

INVOICE

74423

DATE

3-31-26



The information and recommendations provided are based on the images presented by the referring veterinarian. No evaluation can be communicated regarding pathology that was not visible in the image/video clips provided.

Thank you for this referral. If the clinical or image interpretation does not parallel your findings or if I can be of any further assistance please contact me.

Nele Eley (Ondreka), DVM, Dr. med. vet., DipECVDI

European Specialist in Veterinary Diagnostic Imaging, Cert. Radiology,
Senior lecturer University of Giessen/Germany, Veterinary Faculty, Department of Radiology.
info@sonopath.com