



PATIENT

Holly Dewey

SPECIES

Canine

BREED

Australian Shepherd

SEX

FS

AGE

6Y

WEIGHT

18kg

INTERPRETED BY

Nele Eley (Ondreka),
DVM Dr. med. vet.,
DipECVDD

IMAGING PERFORMED BY

David Lane

HOSPITAL NAME

Points East West
Veterinary Services

REFERRING VET

David Lane

INVOICE

74422

DATE

3-31-26

PRESENTING CLINICAL SIGNS

- Chronic LFL lameness
- Examination today revealed substantial pain on left glenohumeral extension and abduction. Mild pain on right glenohumeral abduction
- Sedated examination revealed subjective laxity (soft end feel and increased drawer) of the right shoulder - abduction angle 30 degrees, and normal end feel of left shoulder - abduction angle 25 degrees
- left needle arthroscopy revealed mild villus inflammation of the cranial medial synovium and mild damage of the medial glenohumeral ligament.

ULTRASONOGRAPHIC FINDINGS

Left Shoulder

Average maximum thickness of the left supraspinatus tendon is 6.5mm. There is no evidence of biceps tendon impingement. No structural changes of the supraspinatus tendon are seen.

Mild anechoic effusion is seen within the biceps tendon sheath with associated mild generalized synovial thickening. No structural abnormalities of the biceps tendon are identified. The subscapularis tendon appears normal.

The medial glenohumeral ligament is partially visualized and within normal limits, however, ultrasound assessment is inherently limited and does not fully exclude ligamentous injury.

Right Shoulder

Average maximum thickness of the right supraspinatus tendon is 6.5mm. There is no evidence of biceps tendon impingement. No structural changes of the supraspinatus tendon are seen.

No structural abnormalities of the biceps tendon are identified. There is no evidence of synovial thickening and no evidence of abnormal effusion. The subscapularis tendon appears normal.

The medial glenohumeral ligament is partially visualized and within normal limits, however, ultrasound assessment is inherently limited and does not fully exclude ligamentous injury.

ULTRASONOGRAPHIC DIAGNOSIS

- Mild left bicipital tenosynovitis likely reactive.
- No ultrasonographic evidence of biceps tendon or supraspinatus tendon pathology.
- No definitive sonographic evidence of medial glenohumeral ligament injury – though this cannot be excluded due to methodological limitations.
- Right shoulder unremarkable.

INTERPRETATION OF FINDINGS & FURTHER RECOMMENDATIONS

The mild effusion and synovial thickening of the left biceps sheath are likely secondary/reactive findings rather than a primary tendon lesion given the clinical findings. Partial ligamentous instability remains a strong differential despite inconclusive ultrasound findings. Ultrasound has limited sensitivity for glenohumeral ligament pathology in particular. Correlation with clinical and arthroscopic findings remains most reliable for medial glenohumeral ligament assessment. Consider advanced imaging such as MRI if further characterization is required.



PATIENT

Holly Dewey

SPECIES

Canine

BREED

Australian Shepherd

SEX

FS

AGE

6Y

WEIGHT

18kg

INTERPRETED BY

Nele Eley (Ondreka),
DVM Dr. med. vet.,
DipECVDI

IMAGING PERFORMED BY

David Lane

HOSPITAL NAME

Points East West
Veterinary Services

REFERRING VET

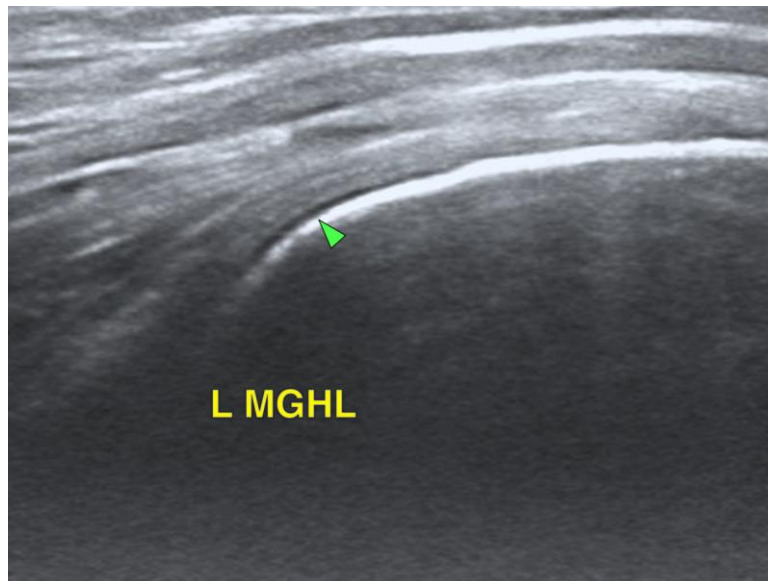
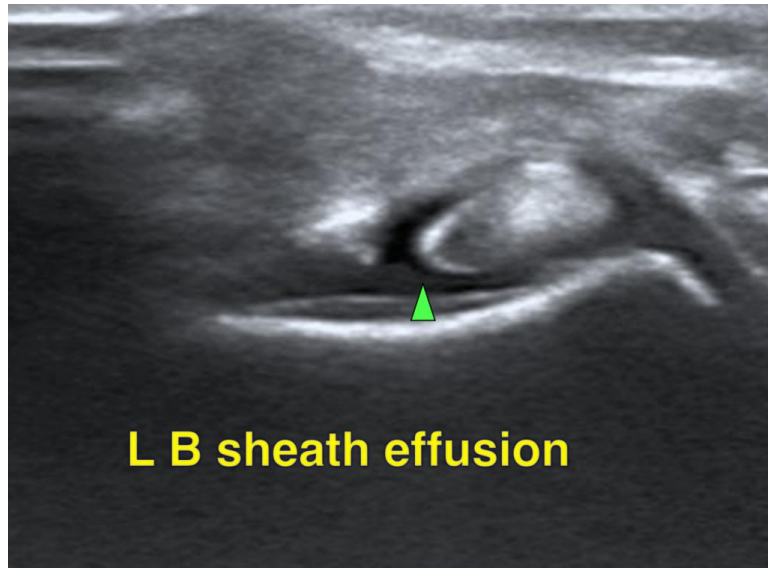
David Lane

INVOICE

74422

DATE

3-31-26



The information and recommendations provided are based on the images presented by the referring veterinarian. No evaluation can be communicated regarding pathology that was not visible in the image/video clips provided.

Thank you for this referral. If the clinical or image interpretation does not parallel your findings or if I can be of any further assistance please contact me.

Nele Eley (Ondreka), DVM, Dr. med. vet., DipECVDI
European Specialist in Veterinary Diagnostic Imaging, Cert. Radiology,
Senior lecturer University of Giessen/Germany, Veterinary Faculty, Department of Radiology.
info@sonopath.com