

**PATIENT**

Zoey Coates

PRESENTING CLINICAL SIGNS

Presented for wellness exam in 5/21 and having trouble with rear leg. Xrays reveal a lumbar-sacral issue. Returne 2/8/2022 Right rear leg is getting worse. Improved with rimadyl. Follow up exam on 3/15/2022 with no improvement with carprofen and gabapentin. Recommended an consultation with orthopedic surgeon and calcaneal tendon ultrasound.

SPECIES

Canine

ULTRASONOGRAPHIC FINDINGS**Right Achilles Tendon**

Regional loss of echoarchitecture, swelling, and decreased echogenicity of the right gastrocnemius tendon are noted close to the insertion to the calcaneal tubercle. Several echogenic structures with distal acoustic shadowing are seen within the altered tendon tissue. Focal surface irregularity of the calcaneus with concave and convex contours is seen. The calcaneal bursa is distended. The superficial digital flexor tendon presents within normal limits. No obvious lesions of the common calcaneal tendon are seen.

BREED

Hound Mix

SEX

FS

Left Achilles Tendon

The left achilles tendon presents within normal limits. There is no evidence of injury of the superficial and deep portions of the calcaneal tendon seen and the bone surface of the calcaneal tubercle presents even and smooth.

AGE

10 Years

ULTRASONOGRAPHIC DIAGNOSIS

- Right gastrocnemius injury with calcaneal avulsion and calcaneal bursitis.

INTERPRETED BY

Nele Eley, DVM
Dr. med. Vet. DipECVDI

INTERPRETATION OF THE FINDINGS & FURTHER RECOMMENDATIONS

The ultrasonographic findings support presence of partial rupture of the right gastrocnemius tendon with avulsion from the calcaneal tubercle and concurrent calcaneal bursitis. Consider chronic degenerative rupture versus acute traumatic injury with the latter being considered slightly less likely based on the ultrasonographic findings.

HOSPITAL NAME

SVS Imaging WI

REFERRING VET

Dr. Herlugson,
Mukwonago Animal
Hospital

INVOICE

51279

DATE

3-31-22



PATIENT

Zoey Coates

SPECIES

Canine

BREED

Hound Mix

SEX

FS

AGE

10 Years

INTERPRETED BY

Nele Eley, DVM
Dr. med. Vet. DipECVDI

HOSPITAL NAME

SVS Imaging WI

REFERRING VET

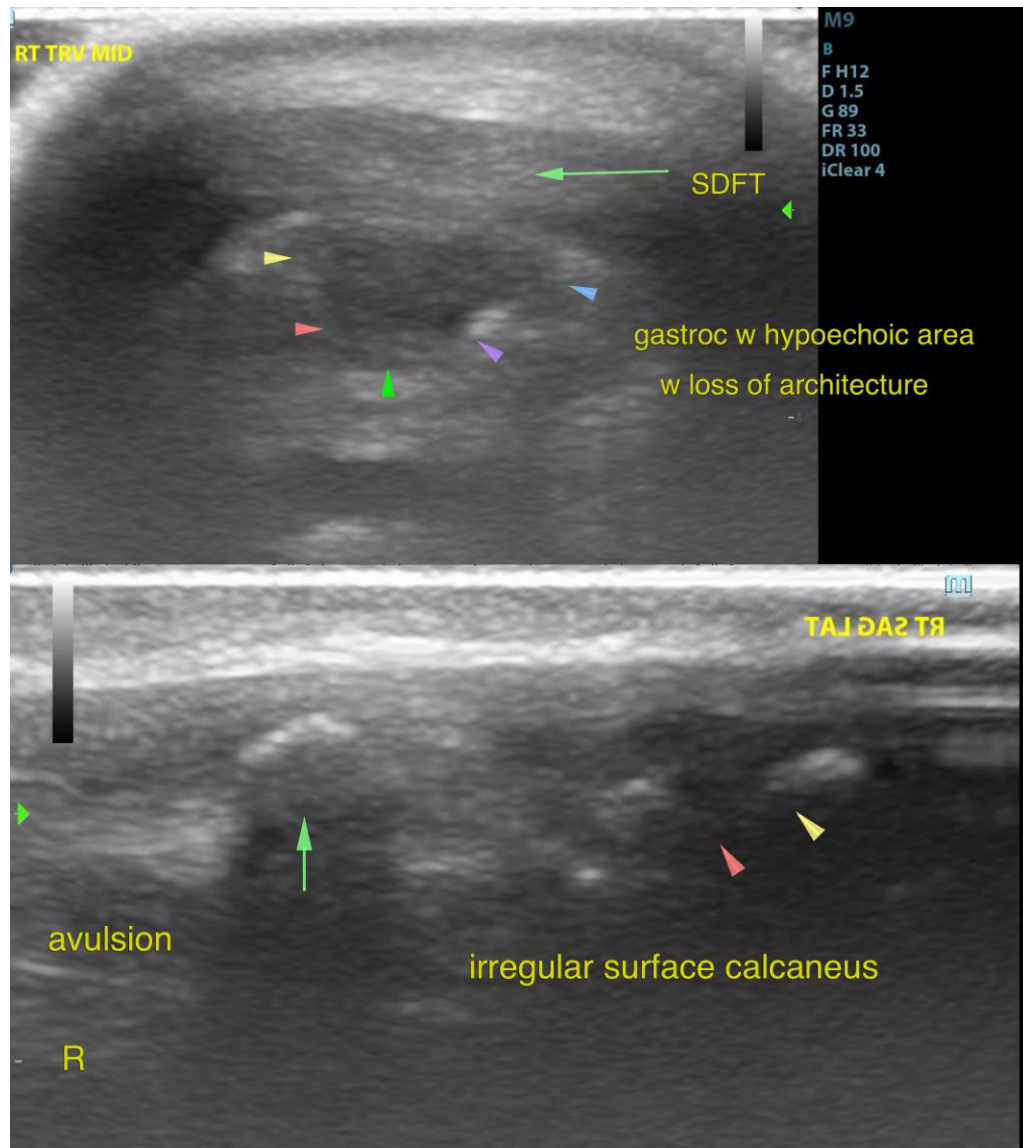
Dr. Herlugson,
Mukwonago Animal
Hospital

INVOICE

51279

DATE

3-31-22



The information and recommendations provided are based on the images presented by the referring veterinarian/sonographer. No evaluation can be communicated regarding pathology that was not visible in the image/video clips provided.

Thank you for this referral. If the clinical or image interpretation does not parallel your findings or if I can be of any further assistance please contact me.

Nele Eley, DVM, Dr. med. vet., DipECVDI
European Specialist in Veterinary Diagnostic Imaging, Cert. Radiology,
Senior lecturer University of Giessen, Germany, Veterinary Faculty, Department of Radiology
Nele.Eley@sonopath.com