



**PATIENT PRESENTING CLINICAL SIGNS**

Fred Munoz S: Pet cough improved alot with medication, O is here for refill O: BAR, m.m-pink, teeth- tartar, OU- severe dry mucoid discharge, AD- severe erythema and discharge, H/L, Abdo, U/G, skin and coat A: Chronic Otitis externa Cough- respiratory vs cardiac vs others

**SPECIES RADIOGRAPHIC STUDY OF THE THORAX & ABDOMEN**

Canine Right/left lateral and ventrodorsal views of the thorax and right lateral and ventrodorsal views of the abdomen totaling 6 images available for review.

**BREED RADIOGRAPHIC FINDINGS**

Cocker Spaniel The patient is obese.

**SEX** Multiple osteoarthritic changes of the bilateral elbows and bilateral stifles are seen.

Male Moderate L2/3 spondylosis deformans is noted as well as narrowing of the lumbosacral intervertebral disc space with vertebral end plate sclerosis and spondylosis deformans.

**AGE Thorax**

14 Years The degree of pulmonary inflation is fair. A moderate bronchointerstitial lung pattern with peribronchial cuffing is noted and evenly distributed throughout the lung. Early cylindrical bronchiectasis appears to be present.

**INTERPRETED BY** Course and width of the trachea are considered within normal limits.

Nele Eley, DVM  
Dr. med. Vet. DipECVDI

The vertebral heart score is 10.4. No specific chamber enlargement is noted. The pulmonary vasculature is within normal limits. There is no evidence of mediastinal widening.

**HOSPITAL NAME Abdomen**

Animal Paradise Hospital The abdominal wall is smooth and thin.

The serosal detail is maintained throughout the peritoneal and retroperitoneal space.

**REFERRING VET** The liver is appropriate in position, size and presents uniform opacity.

Dr. Elshafie The splenic head is in the anticipated position and within normal limits for size and opacity. The splenic body and tail are considered normal for position, size, shape and opacity.

**INVOICE** Both kidneys are seen and present with normal size, shape, delineation and opacity. The urinary bladder is in its anticipated position. No radiopaque calculi are noted throughout the upper and lower urinary tract.

51266

The stomach is in its anticipated position and presents normal content.

**DATE**

3-31-22 The small intestinal loops are of even diameter and non-dilated, a small amount of gas is seen within the small intestinal loops and considered within normal limits.



**PATIENT**

The colon is seen in the expected position and presents with appropriate content.

Fred Munoz

**RADIOGRAPHIC DIAGNOSIS**

**SPECIES**

Canine

- Moderate generalized bronchointerstitial lung pattern with early cylindrical bronchiectasis.
- Normal radiographic presentation of the cardiac silhouette.
- Bilateral stifle and elbow osteoarthritis.
- Degenerative lumbosacral stenosis.
- Spondylosis deformans L2/3.

**BREED**

Cocker Spaniel

**INTERPRETATION OF THE FINDINGS & FURTHER RECOMMENDATIONS**

Based on the radiographic findings, active chronic lower airway disease such as eosinophilic bronchopneumopathy or infectious bronchitis including viral, bacterial, or parasitic should be considered. Further definition may require airway endoscopy with airway sampling.

**SEX**

Male

The radiographic presentation of the cardiac silhouette was within normal limits. No signs of congestive heart failure or left atrial enlargement were identified.

**AGE**

14 Years

**INTERPRETED BY**

Nele Eley, DVM  
Dr. med. Vet. DipECVDI

**HOSPITAL NAME**

Animal Paradise  
Hospital

**REFERRING VET**

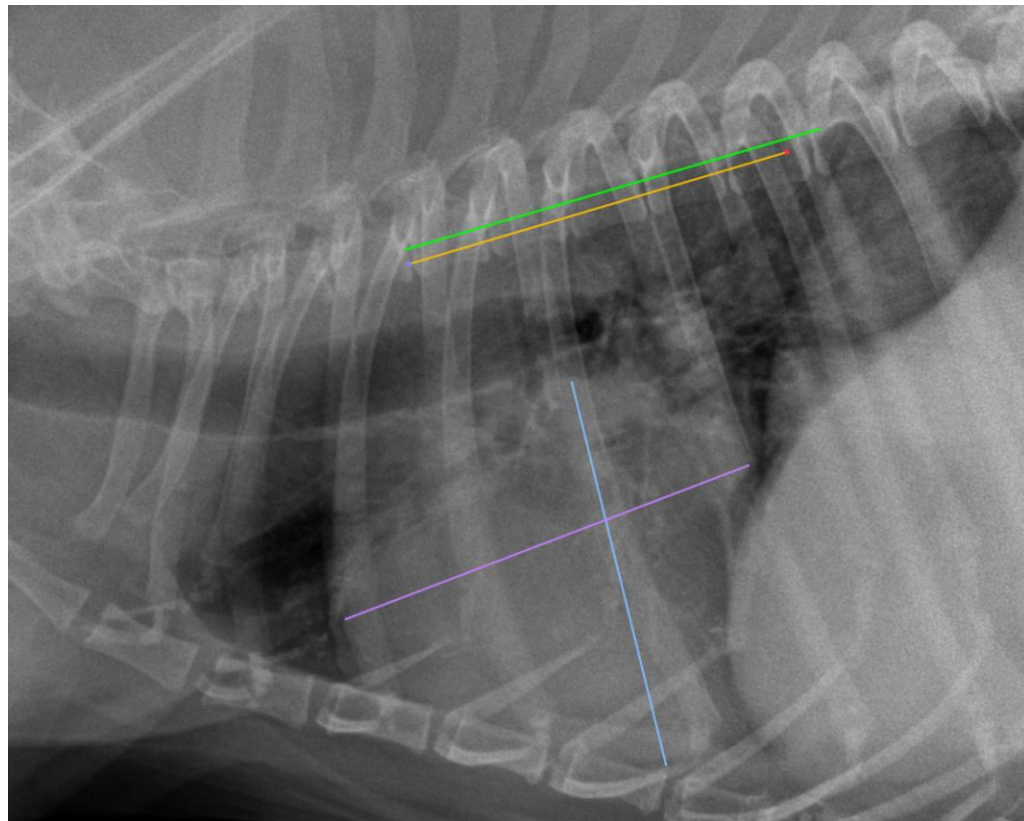
Dr. Elshafie

**INVOICE**

51266

**DATE**

3-31-22





**PATIENT**

Fred Munoz

The information and recommendations provided are based on the images presented by the referring veterinarian/sonographer. No evaluation can be communicated regarding pathology that was not visible in the image/video clips provided.

Thank you for this referral. If the clinical or image interpretation does not parallel your findings or if I can be of any further assistance please contact me.

**SPECIES**

Canine

**Nele Eley**, DVM, Dr. med. vet., DipECVDI  
European Specialist in Veterinary Diagnostic Imaging, Cert. Radiology,  
Senior lecturer University of Giessen, Germany, Veterinary Faculty, Department of Radiology  
Nele.Eley@sonopath.com

**BREED**

Cocker Spaniel

**SEX**

Male

**AGE**

14 Years

**INTERPRETED BY**

Nele Eley, DVM  
Dr. med. Vet. DipECVDI

**HOSPITAL NAME**

Animal Paradise  
Hospital

**REFERRING VET**

Dr. Elshafie

**INVOICE**

51266

**DATE**

3-31-22