



**PATIENT PRESENTING CLINICAL SIGNS**

Cal Warntjes SUP and BB strain RTL suspected 2022 Lameness in the LTL x 2 mos with improvement after one shockwave and rehab Shoulder US submission  
 Abnormal PE/Chem/CBC/UA Results: Painful and stiff LTL biceps with reduced flexibility >> RTL mildly stiff biceps and SUP

**SPECIES**

Canine

**ULTRASONOGRAPHIC FINDINGS**

**Right Shoulder**

The supraspinatus tendon presents moderate echoarchitectural remodeling with partially shadowing echogenic foci concentrated in the mediodistal aspect of the tendon. Tendon thickness is 8mm. Mild osseous remodeling is seen at the bone surface of the greater humeral tubercle. There is mild transverse ligament and biceps impingement. Moderate swelling of the bicipital synovium is seen level with the supraspinatus tendon. Further distal, this tapers down to mild thickening of bicipital synovium. A mild amount of anechoic effusion is present within the bicipital tendon sheath. No evidence of bony exostosis of the intertubercular groove is noted. The visible portion of the medial compartment presents within normal limits. The infraspinatus tendon presents within normal limits.

**BREED**

Australian Shepard Mix

**SEX**

MN

**AGE**

8

**Left Shoulder**

The supraspinatus tendon presents moderate echoarchitectural remodeling with partially shadowing echogenic foci concentrated in the mediodistal aspect of the tendon. Tendon thickness is 8mm. Mild osseous remodeling is seen at the bone surface of the greater humeral tubercle. There is mild transverse ligament and biceps impingement. Moderate swelling of the bicipital synovium is seen level with the supraspinatus tendon. Further distal, this tapers down to mild thickening of bicipital synovium. A mild amount of anechoic effusion is present within the bicipital tendon sheath. No evidence of bony exostosis of the intertubercular groove is noted. The visible portion of the medial compartment presents within normal limits. The infraspinatus tendon presents within normal limits.

**INTERPRETED BY**

Nele Eley, DVM  
 Dr. med. Vet. DipECVCI

**HOSPITAL NAME**

Animal Care Center of  
 Castle Pines

**ULTRASONOGRAPHIC DIAGNOSIS**

- Moderate bilateral supraspinatus tendinopathy with biceps impingement and mild secondary biceps tenosynovitis.

**REFERRING VET**

Bartling

**INTERPRETATION OF THE FINDINGS & FURTHER RECOMMENDATIONS**

The ultrasonographic findings are compatible with bilateral supraspinatus tendinopathy with mild biceps and transverse ligament impingement and mild secondary biceps tenosynovitis. The changes are bilaterally symmetric however, clinical correlation is known to be variable. Consider continuation of the treatment regime based on the clinical findings and clinical response.

**INVOICE**

51277

**DATE**

3-31-22



**PATIENT**

Cal Warntjes

**SPECIES**

Canine

**BREED**

Australian Shepard  
Mix

**SEX**

MN

**AGE**

8

**INTERPRETED BY**

Nele Eley, DVM  
Dr. med. Vet. DipECVDI

**HOSPITAL NAME**

Animal Care Center of  
Castle Pines

**REFERRING VET**

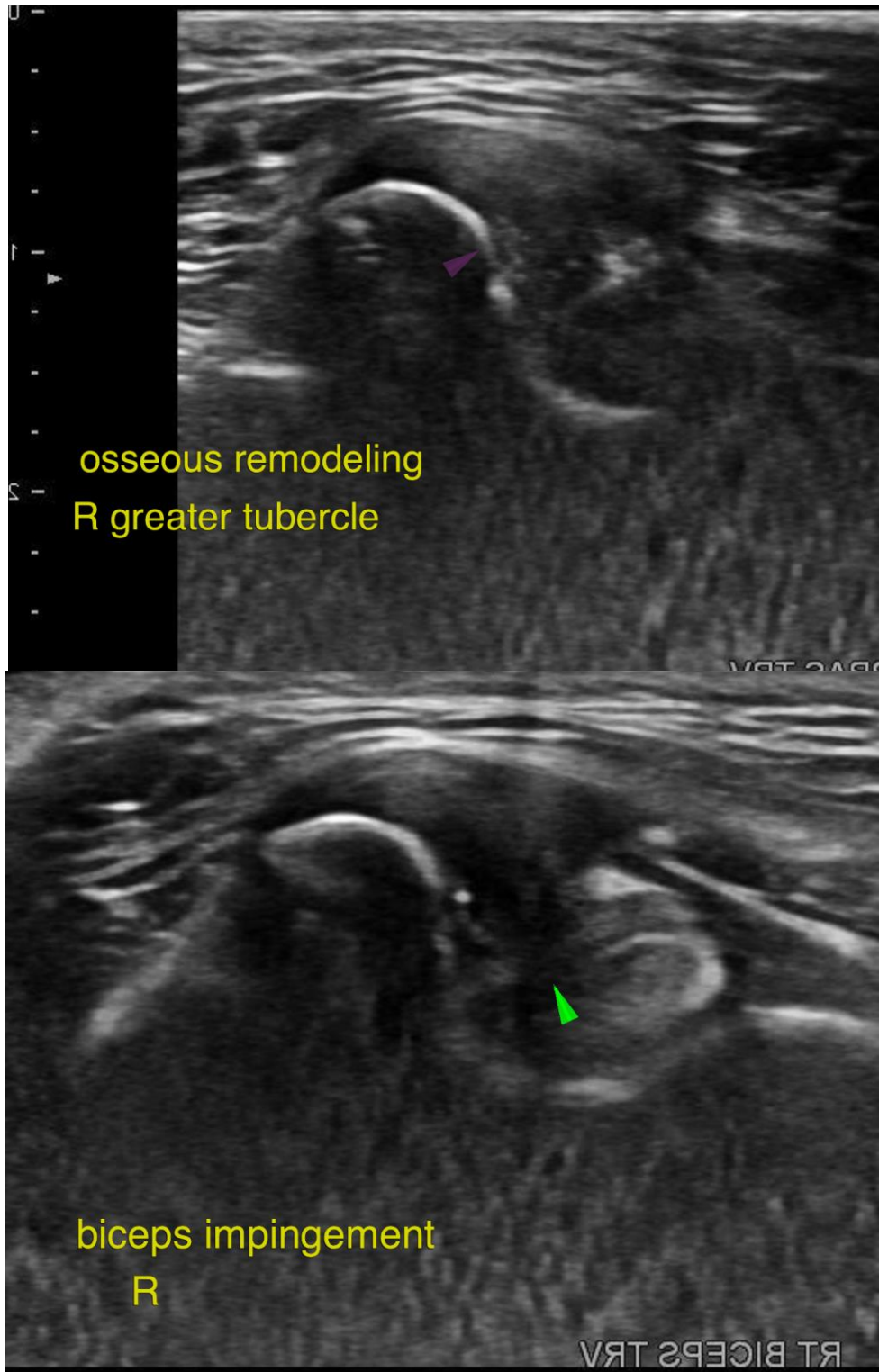
Bartling

**INVOICE**

51277

**DATE**

3-31-22





**PATIENT**

Cal Warntjes

**SPECIES**

Canine

**BREED**

Australian Shepard  
Mix

**SEX**

MN

**AGE**

8

**INTERPRETED BY**

Nele Eley, DVM  
Dr. med. Vet. DipECVDI

**HOSPITAL NAME**

Animal Care Center of  
Castle Pines

**REFERRING VET**

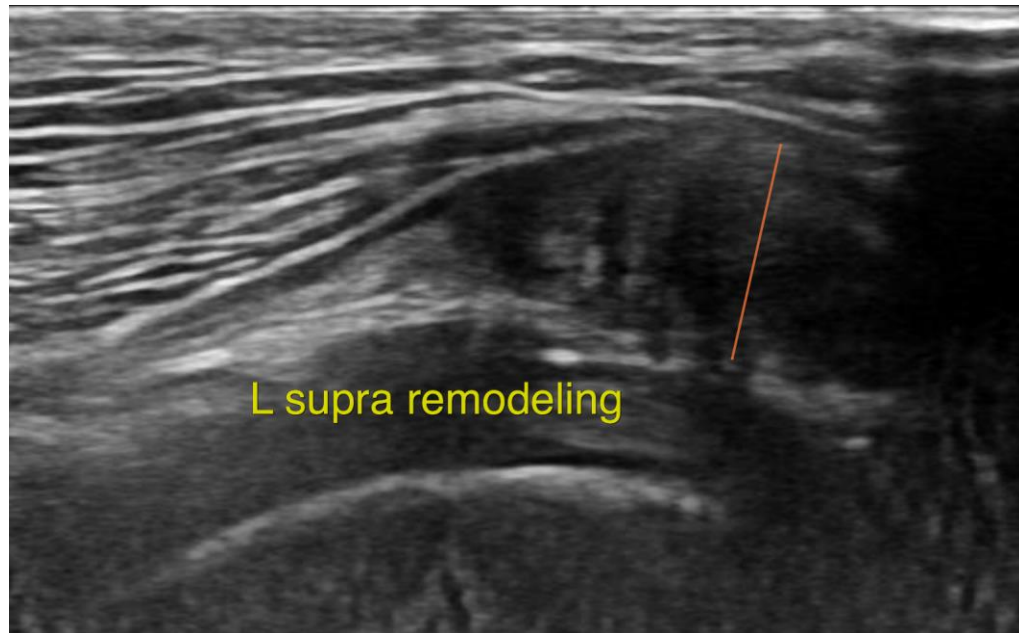
Bartling

**INVOICE**

51277

**DATE**

3-31-22



The information and recommendations provided are based on the images presented by the referring veterinarian/sonographer. No evaluation can be communicated regarding pathology that was not visible in the image/video clips provided.

Thank you for this referral. If the clinical or image interpretation does not parallel your findings or if I can be of any further assistance please contact me.

**Nele Eley**, DVM, Dr. med. vet., DipECVDI  
European Specialist in Veterinary Diagnostic Imaging, Cert. Radiology,  
Senior lecturer University of Giessen, Germany, Veterinary Faculty, Department of Radiology  
Nele.Eley@sonopath.com