



PATIENT

Bernie Cooper

PRESENTING CLINICAL SIGNS

vomiting and diarrhea starting this morning
Abnormal PE/Chem/CBC/UA Results: shaking and rubbing his head during the appointment .
ears and teeth looked normal unremarkable BW

SPECIES

Canine

RADIOGRAPHIC STUDY OF THE ABDOMEN

Right/left lateral and ventrodorsal views totaling 4 images available for review.

BREED

Bluetick Coonhound
Mix

RADIOGRAPHIC FINDINGS

Multiple spondyloses are seen throughout the lumbar spine and lumbosacral junction.

The abdominal serosal detail appears to be mildly reduced in the cranial abdomen.

SEX

Male

The small intestinal loops are evenly distributed throughout the mid abdomen yet turgid in appearance. No evidence of abnormal dilation, plication, or radiopaque foreign material is seen.

Gastric aerophagia is noted without evidence of dilation or displacement.

AGE

10 Years

The kidneys, urinary bladder, and liver present within normal radiographic limits.

RADIOGRAPHIC DIAGNOSIS

- Gastrointestinal maldigestion pattern.
- Mildly reduced abdominal serosal detail.
- Multiple spondyloses.

INTERPRETED BY

Nele Eley, DVM
Dr. med. Vet. DipECVDI

INTERPRETATION OF THE FINDINGS & FURTHER RECOMMENDATIONS

The radiographic findings are negative for mechanical ileus. A gastrointestinal maldigestion pattern is seen which may be due to gastroenteropathy, pancreatopathy, systemic/metabolic disease, or other.

HOSPITAL NAME

St. Catherine's Animal
Hospital

The abdominal serosal detail may be reduced due to crowding of bowel loops in the cranial abdomen; however, regional peritonitis and pancreatopathy cannot be ruled out. Consider further definition by means of abdominal ultrasound.

REFERRING VET

Dr. Mena

INVOICE

51275

DATE

3-31-22



PATIENT

Bernie Cooper

SPECIES

Canine

BREED

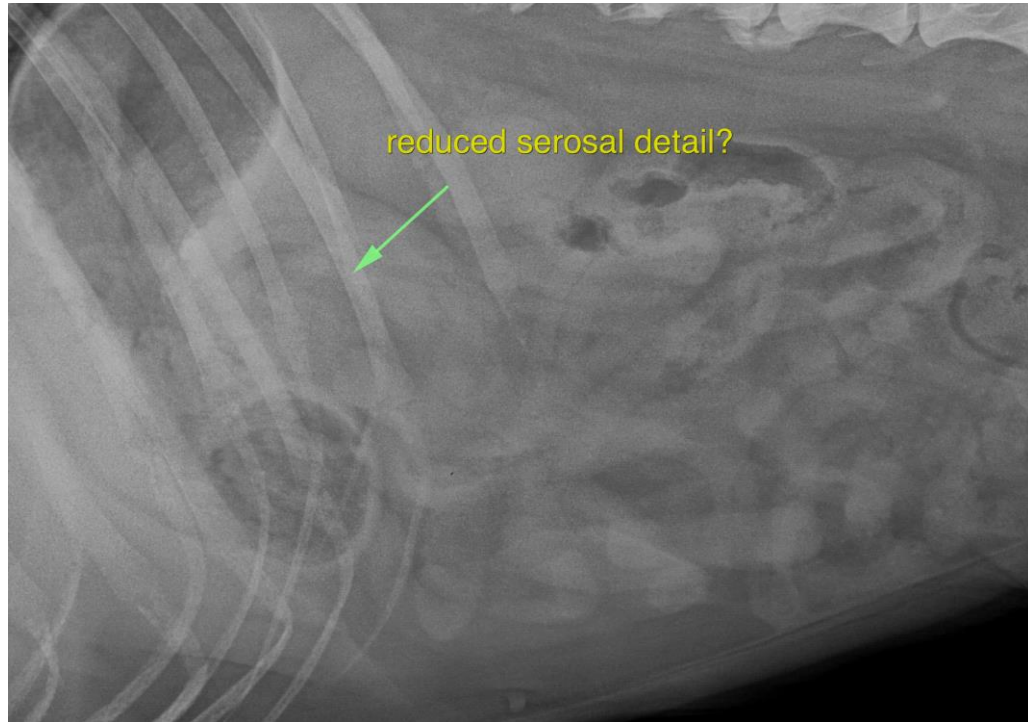
Bluetick Coonhound
Mix

SEX

Male

AGE

10 Years



INTERPRETED BY

Nele Eley, DVM
Dr. med. Vet. DipECVDI

The information and recommendations provided are based on the images presented by the referring veterinarian/sonographer. No evaluation can be communicated regarding pathology that was not visible in the image/video clips provided.

HOSPITAL NAME

St. Catherine's Animal
Hospital

Thank you for this referral. If the clinical or image interpretation does not parallel your findings or if I can be of any further assistance please contact me.

Nele Eley, DVM, Dr. med. vet., DipECVDI
European Specialist in Veterinary Diagnostic Imaging, Cert. Radiology,
Senior lecturer University of Giessen, Germany, Veterinary Faculty, Department of Radiology
Nele.Eley@sonopath.com

REFERRING VET

Dr. Mena

INVOICE

51275

DATE

3-31-22