



## PATIENT

Amber Birsner

## SPECIES

Canine

## BREED

Husky

## SEX

F

## AGE

6Y

## WEIGHT

54lbs

## INTERPRETED BY

Nele Eley (Ondreka),  
DVM Dr. med. vet.,  
DipECVDI

## IMAGING PERFORMED BY

Shari Reffi, CVT

## HOSPITAL NAME

Chester Animal  
Hospital

## REFERRING VET

Dr. Migliaccio

## INVOICE

74386

## DATE

3-30-26

## PRESENTING CLINICAL SIGNS

- 2/25/26-Patient playing w housemate inside. LF triceps injury. Lameness LF grade 1/4
- Tripiceps swelling/sensitivity same area-Rads R/O avulsion of portion of olecranon vs calcification of tendon. (rads attached for reference)
- Current Medications: Rimadyl, Gabapentin (Torb/Midaz for scan)

Abnormal PE/Chem/CBC/UA Results: Anaplasma (+)

## ULTRASONOGRAPHIC FINDINGS

### Left Elbow

There appears to be subacute avulsion of the triceps long and medial heads. A 5mm sized, sharply delineated avulsion fragment is noted with proximal displacement represented by echogenic bone surface with distal acoustic shadowing. The long and medial head of the triceps present overall thickening, ill-defined margination, decreased echogenicity, pockets of fluid accumulation, and disruption of muscle fibers. Multiple small echogenic foci are seen within residual triceps tissue likely representing areas of fibrosis or mineralization. The fragment bed on the olecranon surface is concave corresponding to the displaced avulsion fragment. Overall remodeling of the bone surface of the olecranon is seen.

### Right Elbow

The right elbow presents intact triceps tendons with no avulsion or overt fiber disruption. However, mild overall tendon thickening with multiple small echogenic foci within the tendon suggestive of chronic tendon remodeling are present. Mild remodeling of the olecranon bone surface is noted as well.

## ULTRASONOGRAPHIC DIAGNOSIS

- Subacute triceps avulsion involving mostly long and medial heads of the left triceps with associated muscle disruption and fragment displacement.
- Chronic triceps tendon remodeling of the right triceps.

## INTERPRETATION OF FINDINGS & FURTHER RECOMMENDATIONS

The left elbow demonstrates subacute avulsion of the triceps tendon involving the long and medial heads. The fragment size and proximal displacement suggest that functional failure may be present, and surgical intervention may be required for optimal functional recovery. The echogenic foci within the tendon tissue represents fibrosis or early mineralization consistent with chronic tendon remodeling. Signs of chronic tendon remodeling are present on the right side as well indicating potential bilateral tendinopathy which may reflect repetitive stress with ongoing microfiber damage. Orthopedic consultation for potential surgical repair of the left triceps is recommended if not performed already.



## PATIENT

Amber Birsner

## SPECIES

Canine

## BREED

Husky

## SEX

F

## AGE

6Y

## WEIGHT

54lbs

## INTERPRETED BY

Nele Eley (Ondreka),  
DVM Dr. med. vet.,  
DipECVDI

## IMAGING PERFORMED BY

Shari Reffi, CVT

## HOSPITAL NAME

Chester Animal  
Hospital

## REFERRING VET

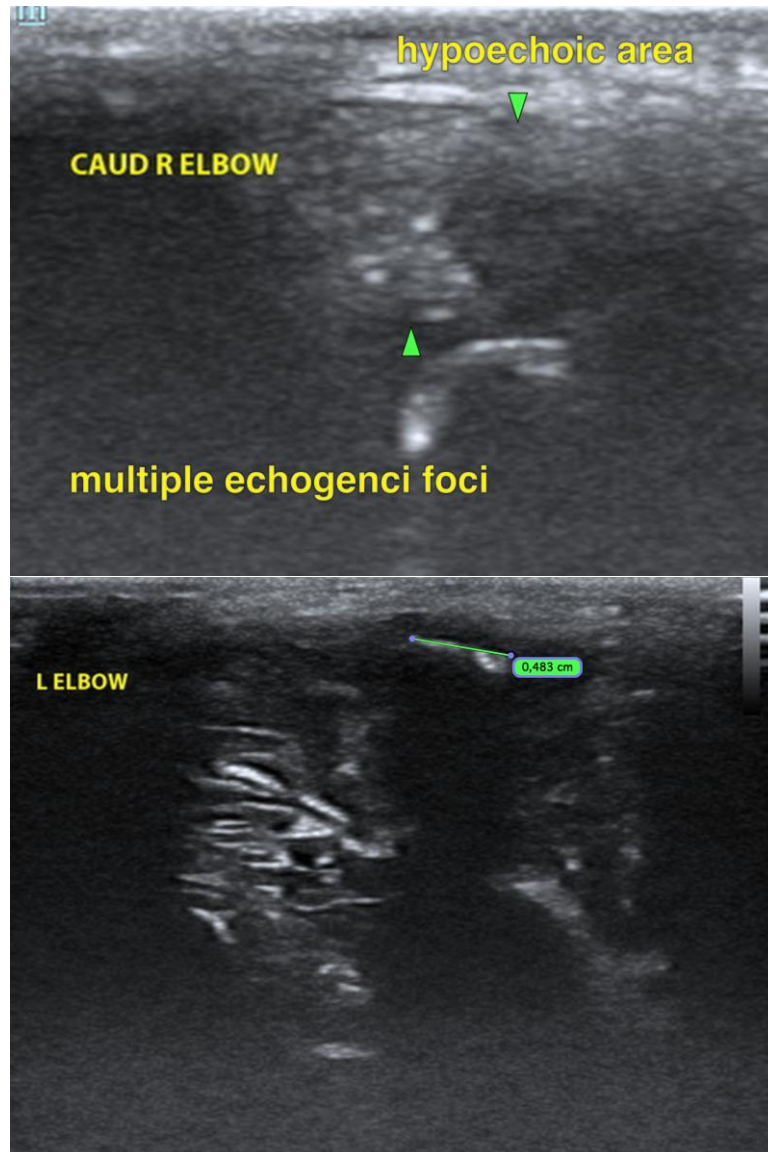
Dr. Migliaccio

## INVOICE

74386

## DATE

3-30-26





## PATIENT

Amber Birsner

## SPECIES

Canine

## BREED

Husky

## SEX

F

## AGE

6Y

## WEIGHT

54lbs

## INTERPRETED BY

Nele Eley (Ondreka),  
DVM Dr. med. vet.,  
DipECVDI

## IMAGING PERFORMED BY

Shari Reffi, CVT

## HOSPITAL NAME

Chester Animal  
Hospital

## REFERRING VET

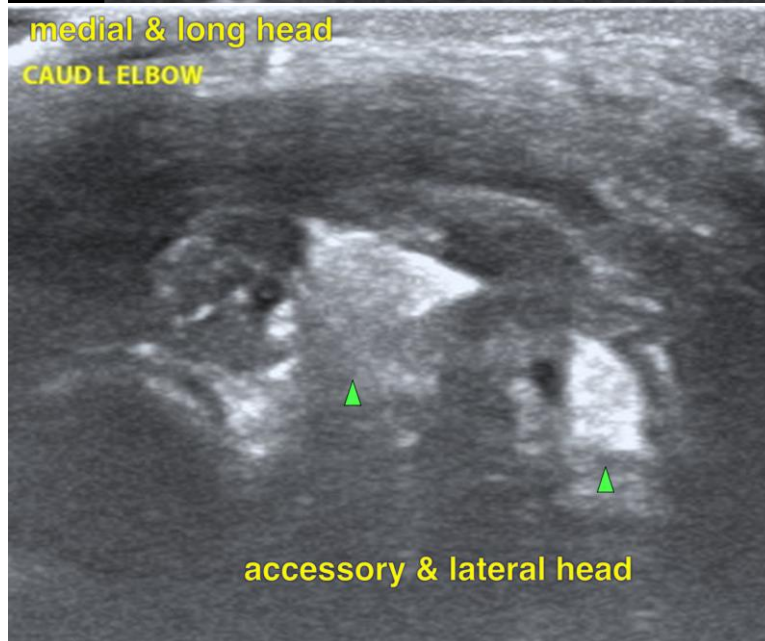
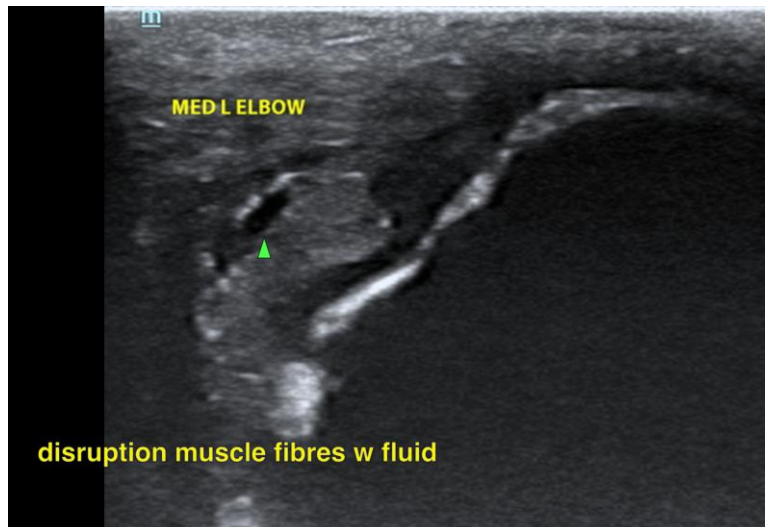
Dr. Migliaccio

## INVOICE

74386

## DATE

3-30-26



The information and recommendations provided are based on the images presented by the referring veterinarian. No evaluation can be communicated regarding pathology that was not visible in the image/video clips provided.

Thank you for this referral. If the clinical or image interpretation does not parallel your findings or if I can be of any further assistance please contact me.

Nele Eley (Ondreka), DVM, Dr. med. vet., DipECVDI  
European Specialist in Veterinary Diagnostic Imaging, Cert. Radiology,  
Senior lecturer University of Giessen/Germany, Veterinary Faculty, Department of Radiology.  
[info@sonopath.com](mailto:info@sonopath.com)