



**PATIENT PRESENTING CLINICAL SIGNS**

Harlin Gore  
Shoulder US RTL > LTL lameness - very painful medial shoulder and SUP  
Abnormal PE/Chem/CBC/UA Results: Moderate elbow OA on rads, IVDD TL and LS, L ACL partial tear, R TPLO Painful and stiff medial shoulder and SUP stretch due to chronic compensation for elbow OA and IVDD

**SPECIES**

Canine

**ULTRASONOGRAPHIC FINDINGS**

**Right Shoulder**

**BREED**

Bulldog

The supraspinatus, deltoideus and infraspinatus muscles present within normal limits for shape, volume, echoarchitecture and echogenicity. The transition to the supraspinatus tendon is even and thin. The broad part of the supraspinatus tendon presents within normal limits for its shape, volume and echogenicity. Average maximum thickness of the supraspinatus tendon is 6mm. There is no evidence of impingement. The attachment to the bone surface of the greater humeral tubercle is even and smooth. The infraspinatus muscle condenses and narrows down to a long tendon of even width, smooth outline and regular echogenic fibular echoarchitecture and up to the attachment to the bone surface of the humerus. There is no evidence of enlargement of the infraspinatus bursa.

**SEX**

MN

**AGE**

10

The biceps tendon can be seen from its origin through the bicipital groove, up to the musculotendinous transition and is within normal limits for shape, echogenicity and echoarchitecture. Mild effusion within the biceps tendon sheath is noted. Minimal bicipital groove exostosis is seen. The cranial part of the medial glenohumeral ligament is seen and presents no significant thickening or disruption. Mild medial subluxation of the humeral head can be provoked.

**INTERPRETED BY**

Nele Eley, DVM  
Dr. med. Vet. DipECVDI

Minimal periarticular bone remodeling is seen.

**Left Shoulder**

**HOSPITAL NAME**

Animal Care Center of  
Castle Pines

The supraspinatus, deltoideus and infraspinatus muscles present within normal limits for shape, volume, echoarchitecture and echogenicity. The transition to the supraspinatus tendon is even and thin. The broad part of the supraspinatus tendon presents within normal limits for its shape, volume and echogenicity. Average maximum thickness of the supraspinatus tendon is 6mm. There is no evidence of impingement. The attachment to the bone surface of the greater humeral tubercle is even and smooth. The infraspinatus muscle condenses and narrows down to a long tendon of even width, smooth outline and regular echogenic fibular echoarchitecture and up to the attachment to the bone surface of the humerus. There is no evidence of enlargement of the infraspinatus bursa.

**REFERRING VET**

Bartling

The biceps tendon can be seen from its origin through the bicipital groove, up to the musculotendinous transition and is within normal limits for shape, echogenicity and echoarchitecture. Mild effusion within the biceps tendon sheath is noted. Minimal bicipital groove exostosis is seen. The cranial part of the medial glenohumeral ligament is seen and presents no significant thickening or disruption. Mild medial subluxation of the humeral head can be provoked.

**INVOICE**

57551

**DATE**

3-30-23

Minimal periarticular bone remodeling is seen.



**PATIENT**

Harlin Gore

**ULTRASONOGRAPHIC DIAGNOSIS**

- Suspect bilateral shoulder instability.
- Normal ultrasonographic presentation of the supraspinatus tendons.
- Mild biceps tendon sheath effusion and early degenerative joint disease of both shoulders.

**SPECIES**

Canine

**INTERPRETATION OF THE FINDINGS & FURTHER RECOMMENDATIONS**

The ultrasonographic study suggests presence of bilateral shoulder laxity which may be due to joint dysplasia or medial shoulder instability. Structural changes of the cranial aspect of the medial glenohumeral ligament were not seen. The mild signs of degenerative joint disease may well be associated with the presumed increased shoulder laxity which would also explain the mild effusion within the bicipital tendon sheaths. No structural evidence of primary supraspinatus or biceps tendinopathy was found.

**BREED**

Bulldog

**SEX**

MN

**AGE**

10

**INTERPRETED BY**

Nele Eley, DVM  
Dr. med. Vet. DipECVDI

**HOSPITAL NAME**

Animal Care Center of  
Castle Pines

**REFERRING VET**

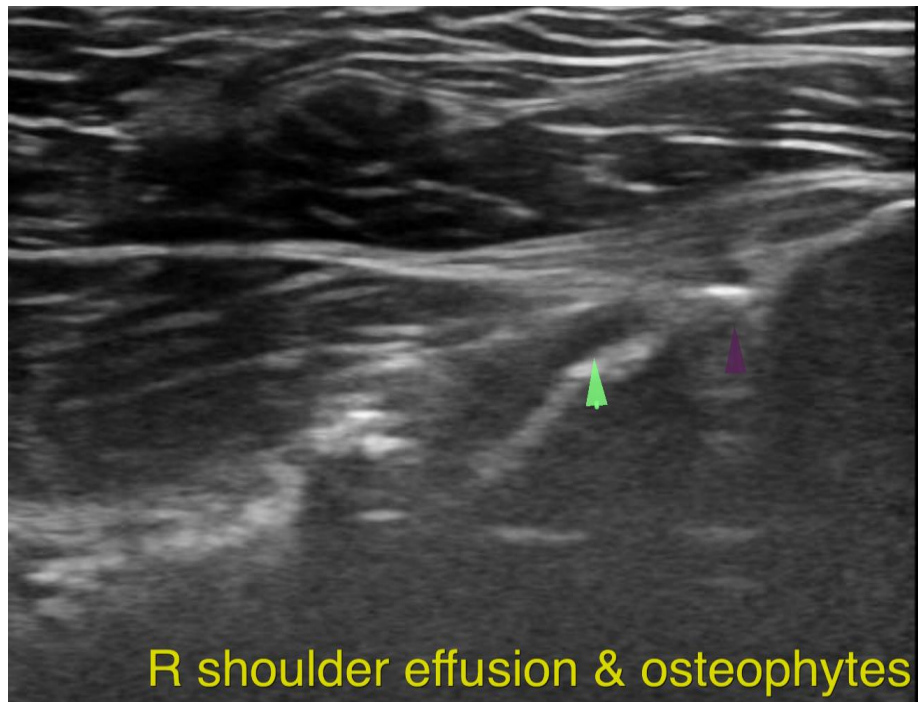
Bartling

**INVOICE**

57551

**DATE**

3-30-23





**PATIENT**

Harlin Gore

**SPECIES**

Canine

**BREED**

Bulldog

**SEX**

MN

**AGE**

10

**INTERPRETED BY**

Nele Eley, DVM  
Dr. med. Vet. DipECVDI

**HOSPITAL NAME**

Animal Care Center of  
Castle Pines

**REFERRING VET**

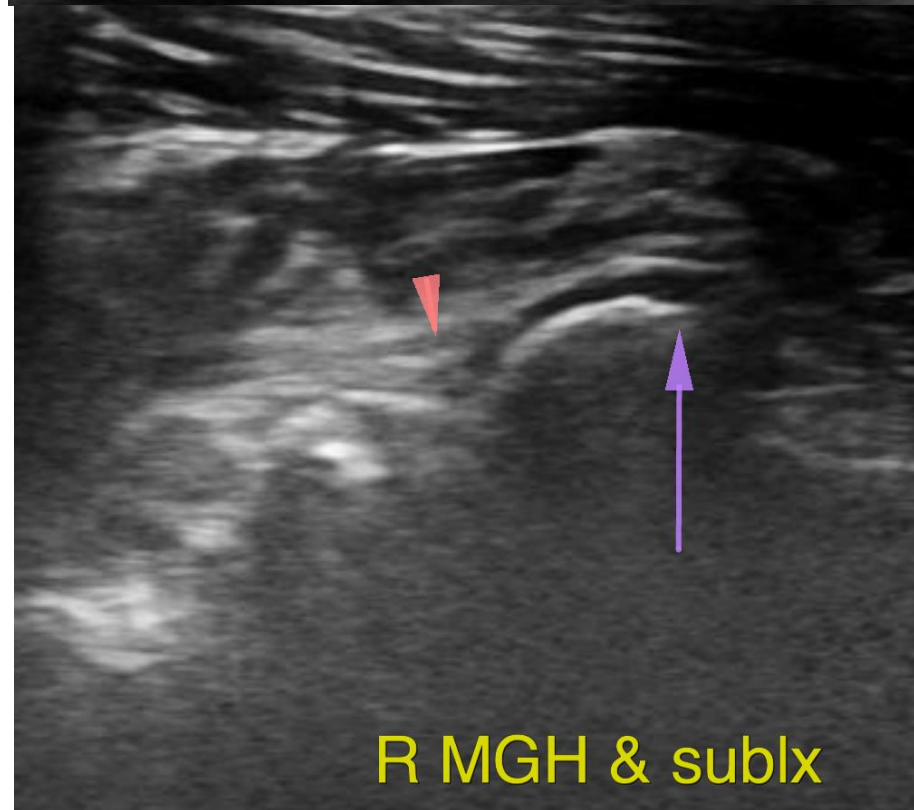
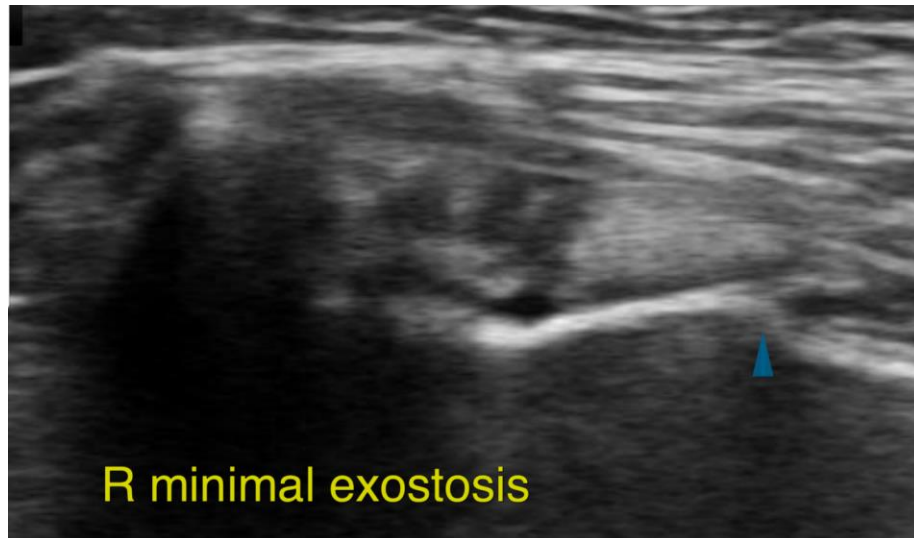
Bartling

**INVOICE**

57551

**DATE**

3-30-23





**PATIENT**

Harlin Gore

The information and recommendations provided are based on the images presented by the referring veterinarian/sonographer. No evaluation can be communicated regarding pathology that was not visible in the image/video clips provided.

Thank you for this referral. If the clinical or image interpretation does not parallel your findings or if I can be of any further assistance please contact me.

**SPECIES**

Canine

**Nele Eley**, DVM, Dr. med. vet., DipECVDI  
European Specialist in Veterinary Diagnostic Imaging, Cert. Radiology,  
Senior lecturer University of Giessen, Germany, Veterinary Faculty, Department of Radiology  
Nele.Eley@sonopath.com

**BREED**

Bulldog

**SEX**

MN

**AGE**

10

**INTERPRETED BY**

Nele Eley, DVM  
Dr. med. Vet. DipECVDI

**HOSPITAL NAME**

Animal Care Center of  
Castle Pines

**REFERRING VET**

Bartling

**INVOICE**

57551

**DATE**

3-30-23