



PATIENT

Lulu Cisneros

PRESENTING CLINICAL SIGNS

Painful lumbar area, HX of back issues

SPECIES

Canine

RADIOGRAPHIC STUDY OF THE THORACOLUMBAR SPINE

Lateral and ventrodorsal views of the thoracic and lumbar spine totaling 2 images available for review.

BREED

Malt/Bichon

RADIOGRAPHIC FINDINGS

Multiple sites of intervertebral disc space narrowing are noted throughout the thoracolumbar spine including T12/13, L4/5, and L5/6.

No evidence of aggressive bone lesions is seen.

SEX

Female/S

There is no evidence of traumatic osseous injury.

AGE

8 Years

RADIOGRAPHIC DIAGNOSIS

- Suspect intervertebral disc disease T12/13, L4/5, and L5/6.

INTERPRETATION OF THE FINDINGS & FURTHER RECOMMENDATIONS

The radiographic findings suggest potential for intervertebral disc disease within the caudal thoracic spine between T12 and T13 as well as within the caudal lumbar spine between L4 and L6. The narrowing of the intervertebral disc space may represent uncomplicated degenerative disc disease. However, disc hernia and other myelopathy cannot be ruled out. Consider further definition by means of cross sectional imaging in case of persisting or deteriorating clinical signs.

INTERPRETED BY

Nele Eley, DVM
Dr. med. Vet. DipECVDI

HOSPITAL NAME

Pacific Avenue
Veterinary Clinic

REFERRING VET

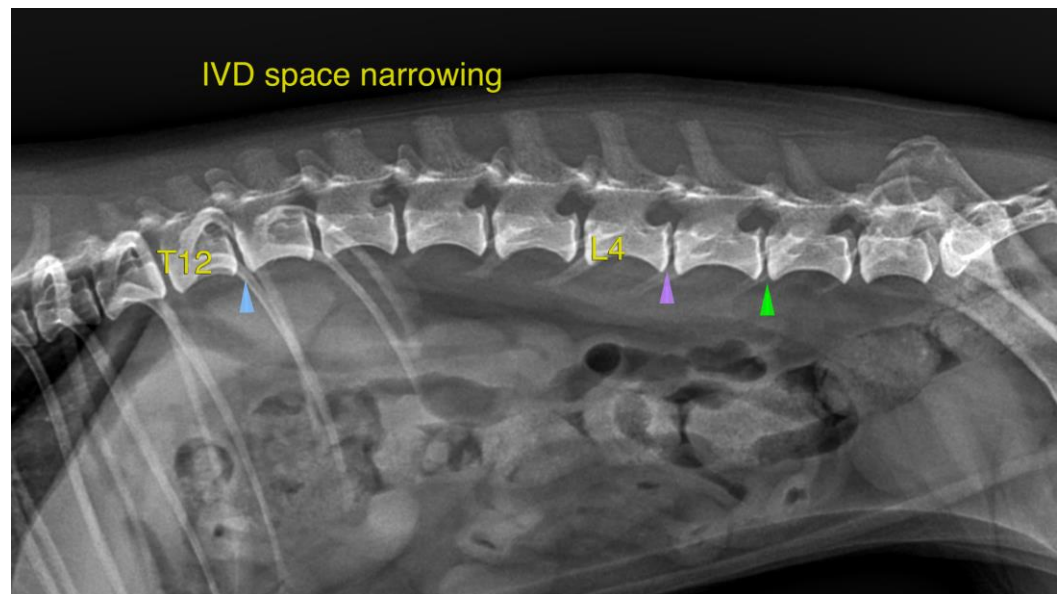
Dr. Sid Bruckert-Frisk

INVOICE

51261

DATE

3-30-22





PATIENT

Lulu Cisneros

The information and recommendations provided are based on the images presented by the referring veterinarian/sonographer. No evaluation can be communicated regarding pathology that was not visible in the image/video clips provided.

SPECIES

Canine

Thank you for this referral. If the clinical or image interpretation does not parallel your findings or if I can be of any further assistance please contact me.

BREED

Malt/Bichon

Nele Eley, DVM, Dr. med. vet., DipECVDI
European Specialist in Veterinary Diagnostic Imaging, Cert. Radiology,
Senior lecturer University of Giessen, Germany, Veterinary Faculty, Department of Radiology
Nele.Eley@sonopath.com

SEX

Female/S

AGE

8 Years

INTERPRETED BY

Nele Eley, DVM
Dr. med. Vet. DipECVDI

HOSPITAL NAME

Pacific Avenue
Veterinary Clinic

REFERRING VET

Dr. Sid Bruckert-Frisk

INVOICE

51261

DATE

3-30-22