



PATIENT

Freedom Capurro

PRESENTING CLINICAL SIGNS

Chronic RH ACL tear with supportive orthotic; chronic bilateral elbow dysplasia. Recent lameness to LF leg and noticed mass developing over left chest lateral wall adjacent to caudal scapular border.

SPECIES

Canine

Abnormal PE/Chem/CBC/UA Results: Large firm mass adherent to scapular caudal border LF; reduced flexion L elbow; Reduced resistance to abduction of shoulder, atrophy to supraspinatus with discomfort on palpation, spasms in teres minor. Fine needle aspirate take for cytology.

BREED

German Shepherd

ULTRASONOGRAPHIC FINDINGS OF THE LEFT SHOULDER & LEFT THORACIC WALL

A large ill-defined irregular shaped expansile soft tissue mass is seen level with the caudodorsal margin of the left scapula. Multiple osseous defects are seen in the proximal and caudal contour of the scapula. Multifocal spiculated new bone formation is present emerging from the remaining osseous margins. The soft tissue component of the mass is severely heterogeneous with predominance of hypoechoic tissue and multifocal cavitation. Moderate vascularity of the soft tissue component of the mass is seen. The size of the mass poses a limitation to the exact measurements. However, the mass measures at least 10 x 8 x 5 cm.

SEX

MN

The supra- and infra- spinatus muscle both present severe atrophy with an overall increase in echogenicity and maintained fibular echoarchitecture. Mild remodeling of the supraspinatus tendon is seen. The biceps tendon presents no echoarchitectural changes. Mild effusion is noted within the bicipital tendon sheath. Interestingly, the teres minor muscle reveals no ultrasonographic signs of atrophy. The muscle echogenicity and echoarchitecture are considered within normal limits.

AGE

11 Years

INTERPRETED BY

Nele Eley, DVM
Dr. med. Vet. DipECVDI

ULTRASONOGRAPHIC DIAGNOSIS

- Expansile mass emerging from the caudoproximal margin of the left scapula with aggressive biological behavior.
- Severe supra- and infra- spinatus muscle atrophy.
- Mild bicipital tendon sheath effusion - translocated effusion from the shoulder joint versus mild tenosynovitis.

HOSPITAL NAME

Cedarview Animal Hospital

INTERPRETATION OF THE FINDINGS & FURTHER RECOMMENDATIONS

The main finding is presence of left scapular mass with aggressive biological behavior. Primary osseous neoplasia with large expansile soft tissue component such as osteosarcoma or chondrosarcoma is considered most likely. However, lymphosarcoma or soft tissue sarcoma with secondary bone lysis cannot be ruled out entirely as a differential diagnosis. Final diagnosis will require sampling. Fine needle aspiration has been performed under ultrasonographic guidance already.

REFERRING VET

Nigel Gumley

INVOICE

51267

Consider staging including fine needle aspiration of the regional lymph nodes, three view thoracic radiographs, and abdominal ultrasound should the owner be interested in pursuing palliative tumor treatment including limb amputation.

DATE

3-30-22



PATIENT

Freedom Capurro

SPECIES

Canine

BREED

German Shepherd

SEX

MN

AGE

11 Years

INTERPRETED BY

Nele Eley, DVM
Dr. med. Vet. DipECVDI

HOSPITAL NAME

Cedarview Animal
Hospital

REFERRING VET

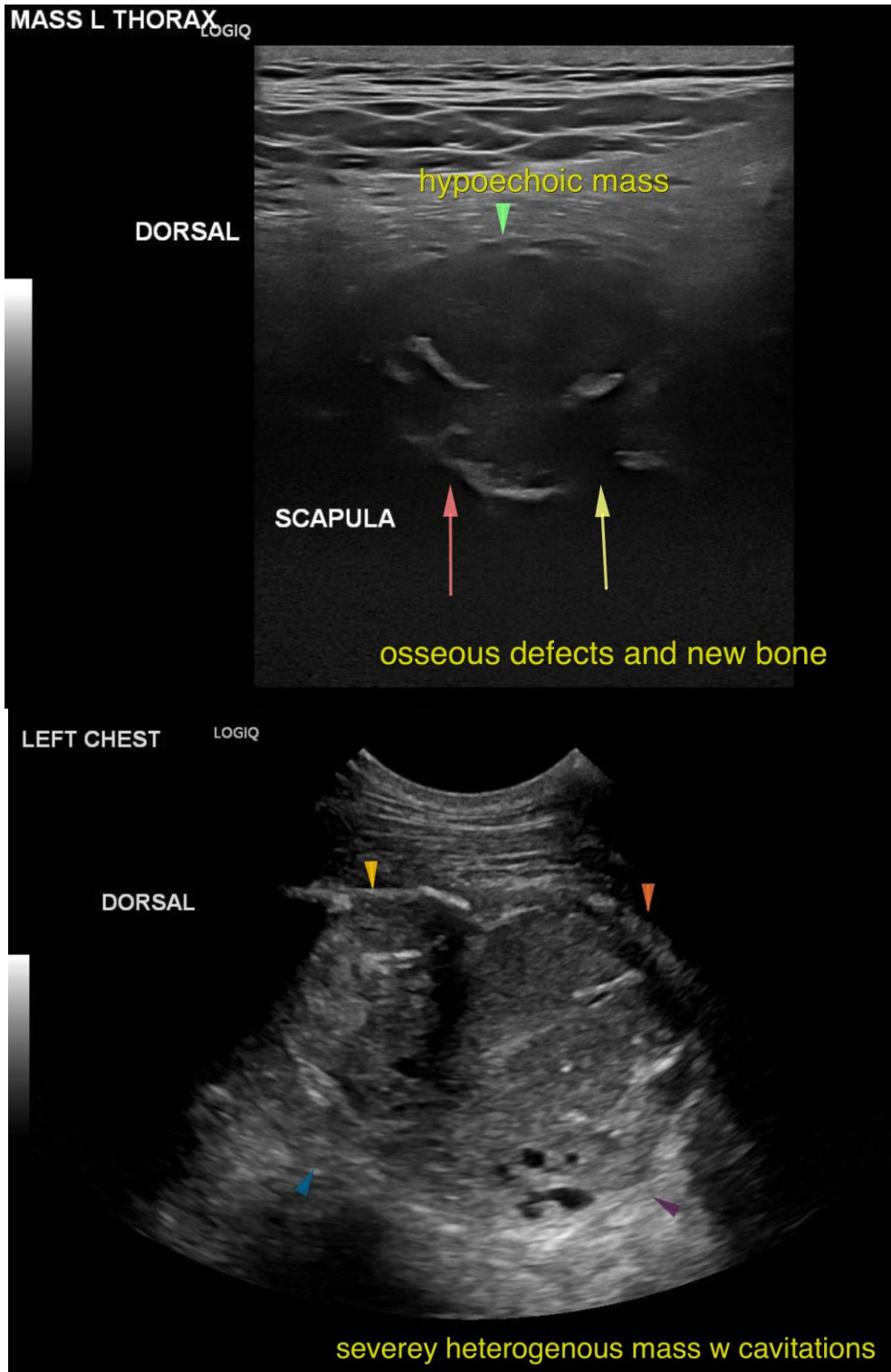
Nigel Gumley

INVOICE

51267

DATE

3-30-22





PATIENT

Freedom Capurro

SPECIES

Canine

BREED

German Shepherd

SEX

MN

AGE

11 Years

INTERPRETED BY

Nele Eley, DVM
Dr. med. Vet. DipECVDI

HOSPITAL NAME

Cedarview Animal
Hospital

REFERRING VET

Nigel Gumley

INVOICE

51267

DATE

3-30-22

The information and recommendations provided are based on the images presented by the referring veterinarian/sonographer. No evaluation can be communicated regarding pathology that was not visible in the image/video clips provided.

Thank you for this referral. If the clinical or image interpretation does not parallel your findings or if I can be of any further assistance please contact me.

Nele Eley, DVM, Dr. med. vet., DipECVDI
European Specialist in Veterinary Diagnostic Imaging, Cert. Radiology,
Senior lecturer University of Giessen, Germany, Veterinary Faculty, Department of Radiology
Nele.Eley@sonopath.com