

**PATIENT**

Fiona Poirier

**PRESENTING CLINICAL SIGNS**

lost control of her back legs last night about 8:00. Dragging hind limbs and unable to move  
Abnormal PE/Chem/CBC/UA Results: \*\*\*Hind limbs defect of proprioceptive, delayed knee reflexes, loss of deep pain sensation. Bloodwork unremarkable

**SPECIES**

Canine

**RADIOGRAPHIC STUDY OF THE CERVICAL, THORACIC, & LUMBAR SPINE**

Lateral views of the cervical, thoracic, and lumbar spine and ventrodorsal hip extended view of the pelvis totaling 4 images available for review.

**BREED**German Shepherd  
Mix**RADIOGRAPHIC FINDINGS**

Number, alignment, and general anatomy of the cervical vertebrae present within normal limits. The craniocervical junction presents within normal limits.

**SEX**

Female Spayed

Moderate ventrally bridging spondylosis deformans is noted between T10 and T11. Mild narrowing of the intervertebral disc space is seen here as well, however, T10/11 also represents the clinal and anticlinal vertebra which typically has a primarily narrow intervertebral disc space.

**AGE**

6 Years

Number, alignment, and anatomy of the lumbar vertebrae present within normal limits. There is no evidence of traumatic osseous injury, discospondylitis, or aggressive bone lesions. No lumbosacral junction abnormality is seen.

The splenic tail is prominent. Consider idiopathic German shepherd dog hypersplenism and other.

**INTERPRETED BY**Nele Eley, DVM  
Dr. med. Vet. DipECVDI**RADIOGRAPHIC DIAGNOSIS**

- Spondylosis deformans T10/11 - otherwise radiographically normal cervical, thoracic, and lumbar spine.

**HOSPITAL NAME**St. Catherine's Animal  
Hospital**INTERPRETATION OF THE FINDINGS & FURTHER RECOMMENDATIONS**

The underlying cause of the acute onset of paraparesis is not evident radiographically. Consider compressive and non-compressive disc hernia, ischemic myelopathy, myelitis, as well as less likely neoplastic or degenerative myelopathies. Further definition by means of an MRI is recommended in case of persistent clinical signs.

**REFERRING VET**

Dr. Mena

**INVOICE**

51270

**DATE**

3-30-22



**PATIENT**

Fiona Poirier

**SPECIES**

Canine

**BREED**

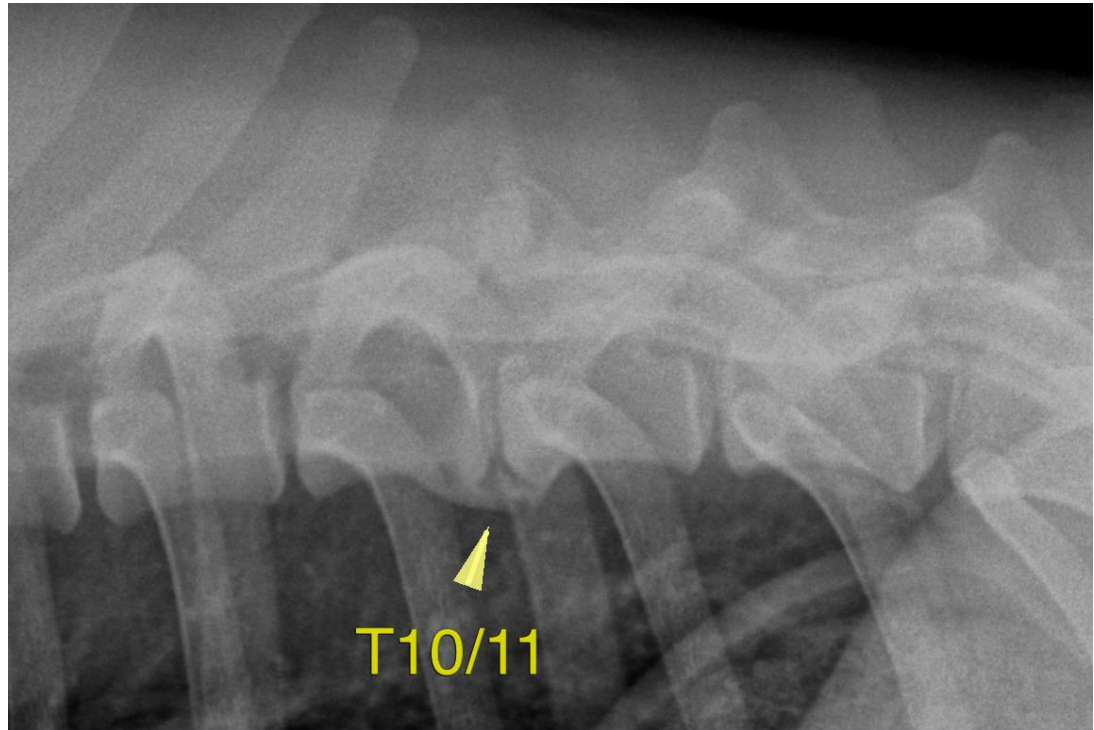
German Shepherd  
Mix

**SEX**

Female Spayed

**AGE**

6 Years



**INTERPRETED BY**

Nele Eley, DVM  
Dr. med. Vet. DipECVDI

The information and recommendations provided are based on the images presented by the referring veterinarian/sonographer. No evaluation can be communicated regarding pathology that was not visible in the image/video clips provided.

**HOSPITAL NAME**

St. Catherine's Animal  
Hospital

Thank you for this referral. If the clinical or image interpretation does not parallel your findings or if I can be of any further assistance please contact me.

**Nele Eley**, DVM, Dr. med. vet., DipECVDI  
European Specialist in Veterinary Diagnostic Imaging, Cert. Radiology,  
Senior lecturer University of Giessen, Germany, Veterinary Faculty, Department of Radiology  
Nele.Eley@sonopath.com

**REFERRING VET**

Dr. Mena

**INVOICE**

51270

**DATE**

3-30-22