



## PATIENT

Poseidon Crumpler

## SPECIES

Canine

## BREED

Pug

## SEX

Intact Male

## AGE

n/a

## WEIGHT

20

## INTERPRETED BY

Nele Eley (Ondreka),  
DVM Dr. med. vet.,  
DipECVDI

## IMAGING PERFORMED BY

WS

## HOSPITAL NAME

Aloha Pet & Bird  
Hospital

## REFERRING VET

Dr. Jose Pepen

## INVOICE

74024

## DATE

3-3-26

## PRESENTING CLINICAL SIGNS

chronic ear infection, no response to medication.

## COMPUTED TOMOGRAPHIC STUDY OF THE HEAD

Plain and post contrast studies are available for review.

## COMPUTED TOMOGRAPHIC FINDINGS

Both tympanic bullae are filled with hypoattenuating contrast negative material. The left bulla presents thickening of its osseous lining. The right tympanic bulla wall is expanded. A soft tissue density within the right external auditory meatus suggests a possible polyp or proliferative lesion. No evidence of intracranial extension is noted. The inner ear presents within normal limits bilaterally. Both external auditory meatuses present thickening of their epithelial lining.

Severe periodontitis is affecting teeth 109, 310, 410, 301, and 402. A dentigerous cyst is present in the right rostral mandible associated with the 402.

No evidence of intracranial mass or aggressive bone disease is seen.

## COMPUTED TOMOGRAPHIC DIAGNOSIS

- Chronic bilateral otitis media with bulla expansion on the right side.
- Right external ear canal mass likely polypoid in nature.
- Severe periodontitis affecting multiple teeth.
- Small dentigerous cyst in right rostral mandible.

## INTERPRETATION OF FINDINGS & FURTHER RECOMMENDATIONS

Chronic otitis media with bulla expansion may predispose to polyp formation or tympanokeratoma formation. The polypoid/proliferative lesion may cause persistent infection or discomfort and should be addressed surgically if medical management fails. Surgical consultation for possible bulla osteotomy and polyp removal is recommended.

Dental evaluation for extraction of affected teeth and removal of dentigerous cyst is recommended as well.



## PATIENT

Poseidon Crumpler

## SPECIES

Canine

## BREED

Pug

## SEX

Intact Male

## AGE

n/a

## WEIGHT

20

## INTERPRETED BY

Nele Eley (Ondreka),  
DVM Dr. med. vet.,  
DipECVDI

## IMAGING PERFORMED BY

WS

## HOSPITAL NAME

Aloha Pet & Bird  
Hospital

## REFERRING VET

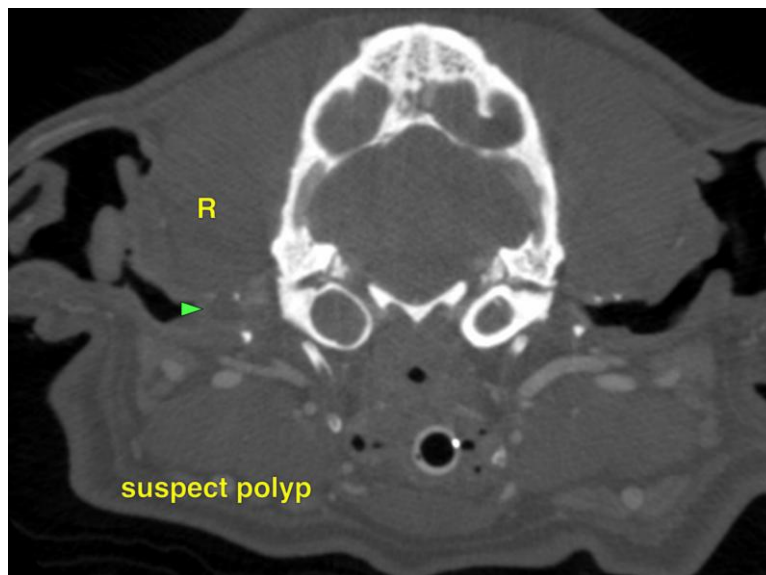
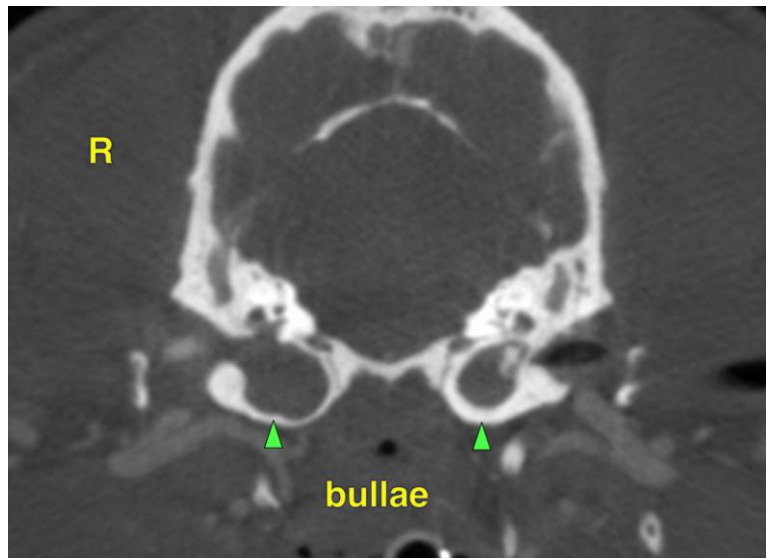
Dr. Jose Pepen

## INVOICE

74024

## DATE

3-3-26



The information and recommendations provided are based on the images presented by the referring veterinarian. No evaluation can be communicated regarding pathology that was not visible in the image/video clips provided.

Thank you for this referral. If the clinical or image interpretation does not parallel your findings or if I can be of any further assistance please contact me.

Nele Eley (Ondreka), DVM, Dr. med. vet., DipECVDI  
European Specialist in Veterinary Diagnostic Imaging, Cert. Radiology,  
Senior lecturer University of Giessen/Germany, Veterinary Faculty, Department of Radiology.

[info@sonopath.com](mailto:info@sonopath.com)