



PATIENT

Morty Werner

SPECIES

Feline

BREED

DSH

SEX

MN

AGE

4Y

WEIGHT

8.7kg

INTERPRETED BY

Nele Eley (Ondreka),
DVM Dr. med. vet.,
DipECVDI

**IMAGING
PERFORMED BY**

Mobile Pet Imaging

HOSPITAL NAME

Mobile Pet Imaging

REFERRING VET

Armstrong

INVOICE

74026

DATE

3-3-26

PRESENTING CLINICAL SIGNS

Pet has a two year history of chronic otitis, has been placed on different courses of antibiotics which make the pet better but for only while taking them. Pet has had bi-lateral ear polyps removed with one of the ears having them in two different occasions. CT recommended for possible surgical planning.

COMPUTED TOMOGRAPHIC STUDY OF THE HEAD

Plain and post contrast studies are available for review.

COMPUTED TOMOGRAPHIC FINDINGS

The patient appears to have a history of left ventral bulla osteotomy. The left bulla is slightly expanded and filled with hypodense material without contrast enhancement. Thickening of the osseous lining accentuated ventrally and caudally is seen. There is a 17 x 5 mm sized soft tissue attenuating elongated mass in the medial aspect of the left external auditory meatus with peripheral contrast enhancement. Thickening of the epithelial lining of the auditory meatus with focal mineralization is seen.

The right tympanic bulla is filled with hypodense material and presents mild smooth thickening of its osseous lining. There is thickening of the epithelial lining of the right external auditory meatus with hypodense luminal material.

A mild amount of fluid attenuating material is seen ventrally within both nasal cavities without evidence of turbinate destruction or foreign material.

The brain presents no deviation from normal anatomy and symmetry. The grey and white matter distinction and the neuroparenchymal attenuation are as expected. The distribution of contrast enhancement is within normal limits throughout the parenchyma and meninges. The ventricular system is non-dilated and within the limits of the expected volume and symmetry.

Both temporomandibular joints present congruent joint spaces with even subchondral bone surfaces and are considered within normal limits.

Moderate bilateral retropharyngeal lymphadenomegaly with nonuniform contrast enhancement is seen.

The salivary glands present within normal limits.

COMPUTED TOMOGRAPHIC DIAGNOSIS

- Suspect recurrent polyp within the left external auditory meatus.
- Chronic left otitis media and externa with post-surgical changes of the left tympanic bulla.
- Chronic right otitis externa and media.
- Moderate bilateral retropharyngeal lymphadenomegaly – likely reactive.
- Mild nondestructive rhinitis bilaterally.

INTERPRETATION OF FINDINGS & FURTHER RECOMMENDATIONS

The mass in the left external auditory meatus is likely to represent a residual or recurring polyp. Early neoplasia cannot be ruled out entirely but is considered less likely. Definitive diagnosis will require histopathology. Note the recurring/persisting chronic bilateral otitis media and externa. Consider repeat removal of the left medial ear canal polyp as well as repeat BO and ear canal ablation owing to the repeatedly recurring nature of the disease.



PATIENT

Morty Werner

SPECIES

Feline

BREED

DSH

SEX

MN

AGE

4Y

WEIGHT

8.7kg

INTERPRETED BY

Nele Eley (Ondreka),
DVM Dr. med. vet.,
DipECVDI

**IMAGING
PERFORMED BY**

Mobile Pet Imaging

HOSPITAL NAME

Mobile Pet Imaging

REFERRING VET

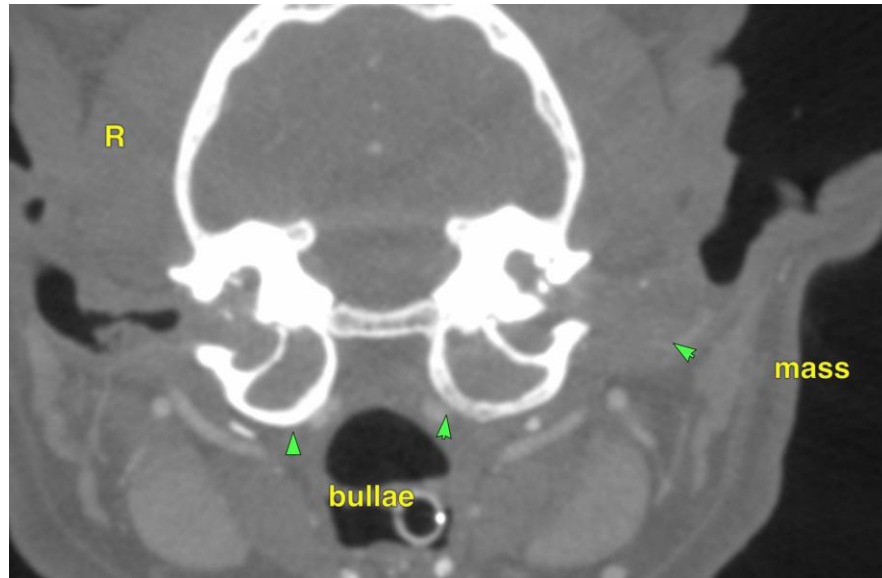
Armstrong

INVOICE

74026

DATE

3-3-26



The information and recommendations provided are based on the images presented by the referring veterinarian. No evaluation can be communicated regarding pathology that was not visible in the image/video clips provided.

Thank you for this referral. If the clinical or image interpretation does not parallel your findings or if I can be of any further assistance please contact me.

Nele Eley (Ondreka), DVM, Dr. med. vet., DipECVDI
European Specialist in Veterinary Diagnostic Imaging, Cert. Radiology,
Senior lecturer University of Giessen/Germany, Veterinary Faculty, Department of Radiology.
info@sonopath.com