

**PATIENT**

Precious Antunes

**SPECIES**

Canine

**BREED**

Lab Mix

**SEX**

F

**AGE**

5 Years

**INTERPRETED BY**Nele Eley, DVM  
Dr. med. Vet. DipECVDI**HOSPITAL NAME**The Pet Hospital of  
Stratford**REFERRING VET**

Dr. Giuliani

**INVOICE**

57058

**DATE**

3-3-23

**PRESENTING CLINICAL SIGNS**

On/off discharge from vulva - Was on abx a couple of months ago from another vet and it cleared but o noted again last week. Yellow in color. P licking excessively. u/d ok No v/d/c/s. Intact. Last heat was September, had a litter 4/2022.

Abnormal PE/Chem/CBC/UA Results: no discharge noted on pe. BAR, rest of pe wnl. bw and urine pending

**RADIOGRAPHIC STUDY OF THE ABDOMEN**

Right/left lateral and ventrodorsal views of the abdomen totaling 4 images available for review.

**RADIOGRAPHIC FINDINGS**

The abdominal serosal detail is maintained.

No uterine body enlargement is seen.

The tubular structures seen in the ventral mid abdomen are compatible with small bowel loops.

The small and large intestine present within normal limits.

The stomach is post-prandial and presents mild aerophagia.

The liver, kidneys, and urinary bladder present within normal limits.

The mamils are prominent.

**RADIOGRAPHIC DIAGNOSIS**

- No radiographic evidence of uterine enlargement or peritonitis.

**INTERPRETATION OF THE FINDINGS & FURTHER RECOMMENDATIONS**

The radiographic study reveals no evidence of uterine enlargement. The sensitivity of radiographs to detect metropathies. However, is limited and further definition by means of abdominal ultrasound and eventual vaginal cytology could be considered in case of persisting clinical signs.



**PATIENT**

Precious Antunes

**SPECIES**

Canine

**BREED**

Lab Mix

**SEX**

F

**AGE**

5 Years

**INTERPRETED BY**

Nele Eley, DVM  
Dr. med. Vet. DipECVDI

**HOSPITAL NAME**

The Pet Hospital of  
Stratford

**REFERRING VET**

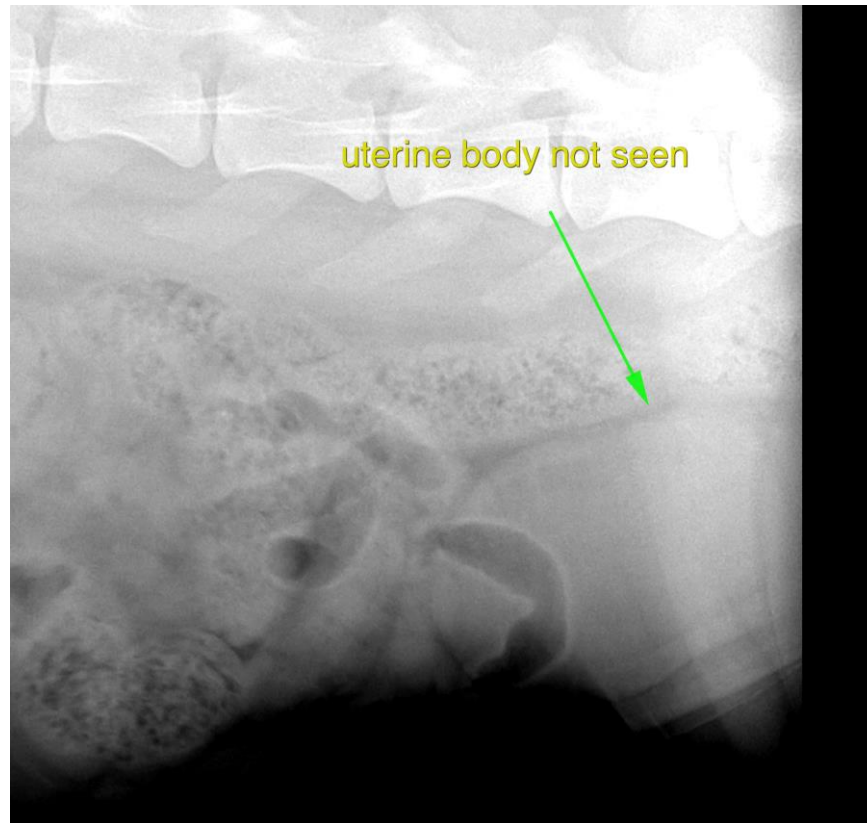
Dr. Giuliani

**INVOICE**

57058

**DATE**

3-3-23



The information and recommendations provided are based on the images presented by the referring veterinarian/sonographer. No evaluation can be communicated regarding pathology that was not visible in the image/video clips provided.

Thank you for this referral. If the clinical or image interpretation does not parallel your findings or if I can be of any further assistance please contact me.

**Nele Eley**, DVM, Dr. med. vet., DipECVDI  
European Specialist in Veterinary Diagnostic Imaging, Cert. Radiology,  
Senior lecturer University of Giessen, Germany, Veterinary Faculty, Department of Radiology  
Nele.Eley@sonopath.com