

**PATIENT PRESENTING CLINICAL SIGNS**

Hercules Luna Paraparesis, presented for surgical consult. Previous dog attack, sutures present in the Right thigh area.
Abnormal PE/Chem/CBC/UA Results: Shaved area, road rash over Right gluteal area.

SPECIES COMPUTED TOMOGRAPHIC STUDY OF THE THORACOLUMBAR SPINE

Canine Plain study and CT myelogram with lumbar puncture available for review.

BREED COMPUTED TOMOGRAPHIC FINDINGS

Lhasa Apso Fracture of the right cranial articular process of the 4th lumbar vertebra is seen with right vertebral facet joint fracture and subluxation. Mild rotation of the spine is noted at the same level. The intervertebral disc is mildly reduced in width. The myelogram reveals moderate generalized spinal cord swelling throughout the length of L3 and L4. Moderate to severe extradural spinal cord compression by means of isoattenuating material within the right epidural space is seen level with the intervertebral disc space L3/4. Approximately 50% of the vertebral canal's cross sectional area appear to be occupied by the extradural material.

SEX

Male Intact

AGE

10 Years, 2 Months

COMPUTED TOMOGRAPHIC DIAGNOSIS

- Traumatic right facet joint fracture L3/4 with vertebral subluxation and moderate to severe right hand sided extradural spinal cord compression.
- Spinal cord swelling throughout L3 & L4.

INTERPRETED BY INTERPRETATION OF FINDINGS & FURTHER RECOMMENDATIONS

Nele Eley (Ondreka),
DVM Dr. med. vet.,
DipECVDI
The CT study reveals traumatic osseous injury of the lumbar spine level with the L3/4 intervertebral disc space. Right vertebral facet joint fracture and subluxation is seen concurred by moderate to severe right hand sided extradural spinal cord compression. The isoattenuating material within the right epidural space may represent nucleus pulposus (traumatic disc extrusion) or hemorrhage as well as a combination of these. Decompressive surgery is indicated based on the degree of spinal cord compression depending on the correlation with the clinical signs.

HOSPITAL NAME

Mobile Pet Imaging

REFERRING VET

Meaux

INVOICE

57531

DATE

3-29-23



PATIENT

Hercules Luna

SPECIES

Canine

BREED

Lhasa Apso

SEX

Male Intact

AGE

10 Years, 2 Months

INTERPRETED BY

Nele Eley (Ondreka),
DVM Dr. med. vet.,
DipECVDI

HOSPITAL NAME

Mobile Pet Imaging

REFERRING VET

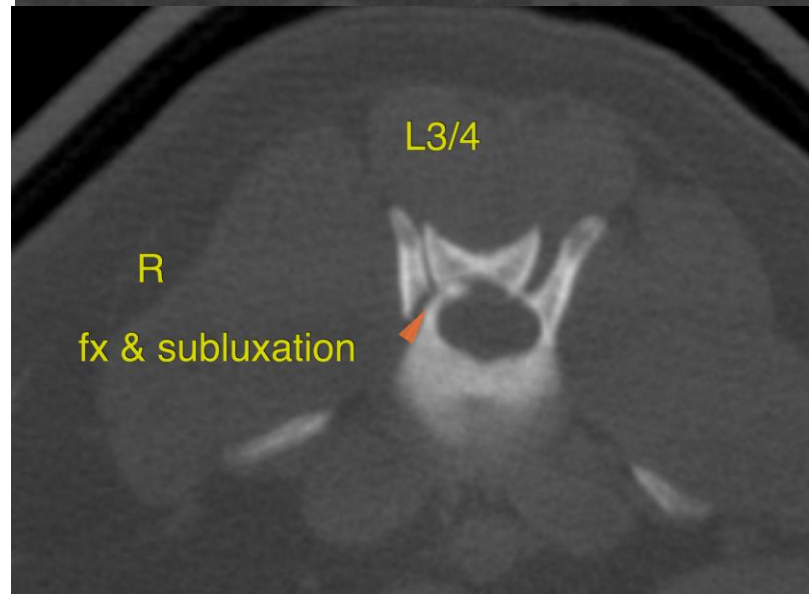
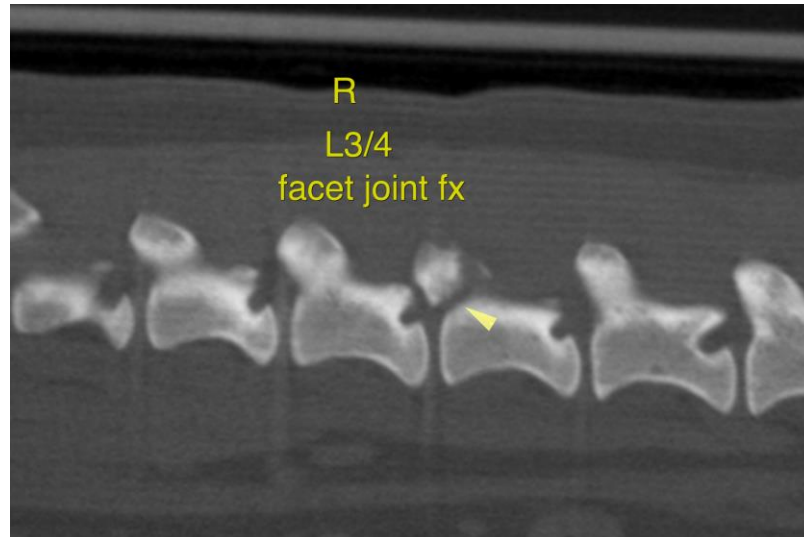
Meaux

INVOICE

57531

DATE

3-29-23





PATIENT

Hercules Luna

SPECIES

Canine

BREED

Lhasa Apso

SEX

Male Intact

AGE

10 Years, 2 Months

INTERPRETED BY

Nele Eley (Ondreka),
DVM Dr. med. vet.,
DipECVDI

HOSPITAL NAME

Mobile Pet Imaging

REFERRING VET

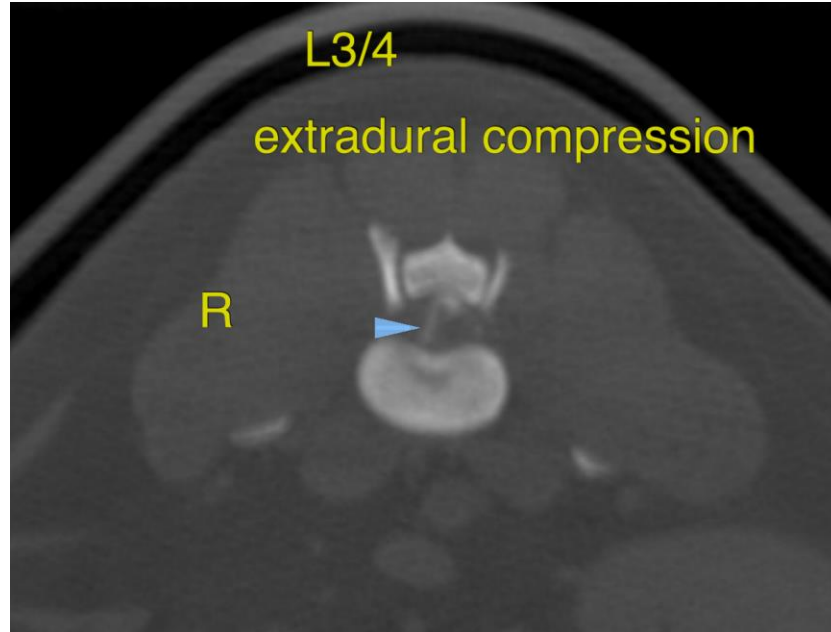
Meaux

INVOICE

57531

DATE

3-29-23



The information and recommendations provided are based on the images presented by the referring veterinarian. No evaluation can be communicated regarding pathology that was not visible in the image/video clips provided.

Thank you for this referral. If the clinical or image interpretation does not parallel your findings or if I can be of any further assistance please contact me.

Nele Eley (Ondreka), DVM, Dr. med. vet., DipECVDI
European Specialist in Veterinary Diagnostic Imaging, Cert. Radiology,
Senior lecturer University of Giessen/Germany, Veterinary Faculty, Department of Radiology.
Nele.Eley@sonopath.com