


**PATIENT PRESENTING CLINICAL SIGNS**

Penelope McShea

Penelope is a thirteen year old, FS, DSH cat with a long history of back pain and mobility issues, even prior to her becoming a patient of our hospital. In the past, Penelope had been treated by a chiropractor. She is currently being treated with meloxidyl PO SID, gabapentin as needed, and the Assisi Loop Bed once to twice daily. Penelope was presented today for a dental prophylactic cleaning. Her owner requested spinal radiographs as she has had pain in the T13-L1 area.

**SPECIES**

Feline

**RADIOGRAPHIC STUDY OF THE LUMBAR SPINE**
**BREED**

DSH

Lateral and ventrodorsal views totaling two images provided for review.

**RADIOGRAPHIC FINDINGS**
**SEX**

Spayed Female

Number, alignment, and general anatomy of the thoracic and lumbar vertebrae present within normal limits. The intervertebral disc spaces are of even width. The vertebral endplates are well delineated. There is no evidence of aggressive bone lesions, spondyloses, or spondyloarthropathy throughout the thoracic and lumbar spine.

A mild generalized bronchial lung pattern is noted.

**AGE**

13 Years

**RADIOGRAPHIC DIAGNOSIS**

- Normal age related thoracolumbar spine

**INTERPRETED BY**

Nele Eley (Ondreka),  
 DVM Dr. med. vet.,  
 DipECVDI

**INTERPRETATION OF FINDINGS & FURTHER RECOMMENDATIONS**

The radiographic study reveals no evidence of structural pathology throughout the thoracic and lumbar spine. The findings are considered within age related normal limits. Radiographically occult intervertebral disc disease or myelopathy cannot be ruled out, and further workup by means of cross sectional imaging could be considered at any time if the patient develops neurologic signs.

**HOSPITAL NAME**

Lambs Gap AH

**REFERRING VET**

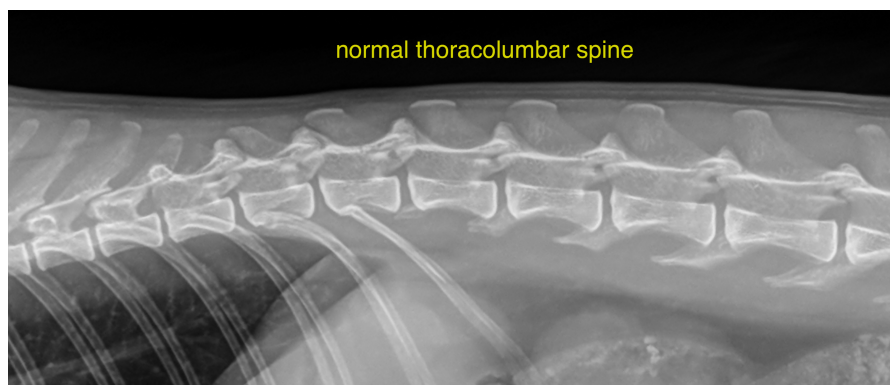
Dr. Lindsey Knouse

**INVOICE**

36535

**DATE**

3/29/22





**PATIENT**

Penelope McShea

The information and recommendations provided are based on the images presented by the referring veterinarian. No evaluation can be communicated regarding pathology that was not visible in the image/video clips provided.

**SPECIES**

Feline

Thank you for this referral. If the clinical or image interpretation does not parallel your findings or if I can be of any further assistance please contact me.

**BREED**

DSH

**Nele Eley (Ondreka)**, DVM, Dr. med. vet., DipECVDI  
European Specialist in Veterinary Diagnostic Imaging, Cert. Radiology,  
Senior lecturer University of Giessen/Germany, Veterinary Faculty, Department of Radiology.  
Nele.Eley@sonopath.com

**SEX**

Spayed Female

**AGE**

13 Years

**INTERPRETED BY**

Nele Eley (Ondreka),  
DVM Dr. med. vet.,  
DipECVDI

**HOSPITAL NAME**

Lambs Gap AH

**REFERRING VET**

Dr. Lindsey Knouse

**INVOICE**

36535

**DATE**

3/29/22