

**PATIENT**

Lou Virgin

PRESENTING CLINICAL SIGNS

Intermit lameness for the past 2 weeks. Buttress and effusion noted on exam. Suspect partial unstable tear based on exam. 4dx neg
Abnormal PE/Chem/CBC/UA Results: N/A

SPECIES

Canine

ULTRASONOGRAPHIC STUDY OF THE STIFLE

Laterality not specified.

BREED

Lab X

ULTRASONOGRAPHIC FINDINGS

A moderate amount of anechoic effusion is seen within the infrapatellar recess of the stifle joint. There is moderate heterogeneity of the infrapatellar fat pad.

SEX

FS

The cranial cruciate ligament presents mostly continuous however is thick with ill-defined margins and altered internal echoarchitecture with small echogenic foci.

AGE

5 Years

ULTRASONOGRAPHIC DIAGNOSIS

- Stifle arthropathy with cranial cruciate ligament pathology effusion, and synovialitis.

INTERPRETATION OF THE FINDINGS & FURTHER RECOMMENDATIONS

The ultrasonographic study reveals effusion and synovialitis within the stifle joint as well as altered echoarchitecture of the cranial cruciate ligament compatible with partial rupture. Based on the ultrasonographic findings, this may represent a relatively early stage of partial ligament injury yet biomechanical failure has to be assumed and surgical intervention could be considered in order to prevent further damage to the articular structures.

INTERPRETED BY

Nele Eley, DVM
Dr. med. Vet. DipECVDI

HOSPITAL NAME

Foxfield Veterinary
Services

REFERRING VET

A, Rodriguez

INVOICE

51234

DATE

3-29-22



PATIENT

Lou Virgin

SPECIES

Canine

BREED

Lab X

SEX

FS

AGE

5 Years

INTERPRETED BY

Nele Eley, DVM
Dr. med. Vet. DipECVDI

HOSPITAL NAME

Foxfield Veterinary
Services

REFERRING VET

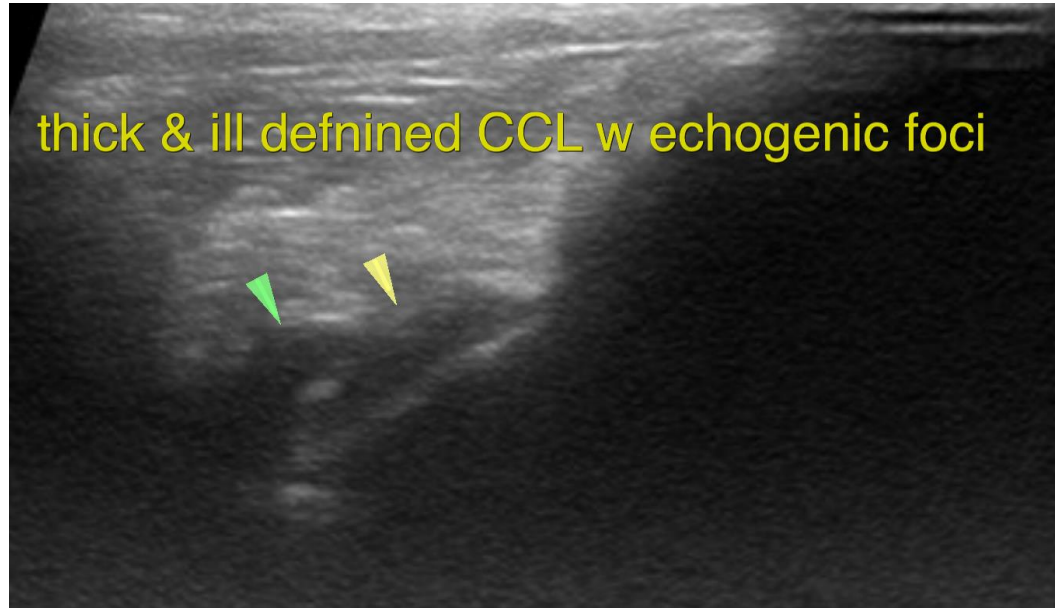
A, Rodriguez

INVOICE

51234

DATE

3-29-22



The information and recommendations provided are based on the images presented by the referring veterinarian/sonographer. No evaluation can be communicated regarding pathology that was not visible in the image/video clips provided.

Thank you for this referral. If the clinical or image interpretation does not parallel your findings or if I can be of any further assistance please contact me.

Nele Eley, DVM, Dr. med. vet., DipECVDI
European Specialist in Veterinary Diagnostic Imaging, Cert. Radiology,
Senior lecturer University of Giessen, Germany, Veterinary Faculty, Department of Radiology
Nele.Eley@sonopath.com